


# NYS DJ

Volume 81 **Number 6**

November **2015**



**Cover:** While attitudes of dental students have been widely measured, the perceptions of dental faculty have been evaluated to a much lesser degree. When both were queried, several significant differences were uncovered.

- 2** Editorial  
*End impediments to licensure*
- 6** Attorney on Law  
*Employment law gets upgrades*
- 10** Letters
- 12** Viewpoint  
*Showing the way*
- 14** Association Activities
- 55** General News
- 58** Component News
- 68** Read, Learn, Earn
- 70** Books
- 73** Classifieds
- 76** Index to Advertisers
- 80** Addendum

The New York State Dental Journal is a peer reviewed publication. Opinions expressed by the authors of material included in The New York State Dental Journal do not necessarily represent the policies of the New York State Dental Association or The New York State Dental Journal. EZ-Flip version of The NYS DJ is available at [www.nysdental.org](http://www.nysdental.org) and can be downloaded to mobile devices.

## **23 Contrasting Perspectives of Dental Faculty and Their Students Concerning Dental Academia**

*Ahmad Abdelkarim, D.D.S., M.S., Ph.D. Ed.D.; Donna Sullivan, Ph.D.*

Attitudes of dental students and faculty towards research, faculty recruitment, new school openings and academic career rewards and disadvantages were evaluated. Both groups said there is no significant need for new dental schools.

## **30 Risk Factors in the Development of Oral Bisphosphonate-induced Osteonecrosis**

*Stacey Reiss, D.D.S.; Daniel Sultan, D.D.S.*

Bisphosphonate-associated osteonecrosis of the jaw is a rare, but serious complication, most often following extraction in patients treated with intravenous BPs. Authors aim to construct a clinically relevant predictive model of the disease through better understanding of concomitant risk factors.

## **34 Occlusal Characteristics of the Primary Dentition Revisited**

*Stanley A. Alexander, D.M.D.; Marjan Askari, D.M.D., M.S.; Patricia Lewis, D.D.S., M.P.H.*

The occlusal characteristics of the primary dentition of 130 children 3 to 6 years old were examined. Among study findings, the majority of children were considered to have a normal overbite.

## **40 Multiple Radiolucencies of the Jaws in a 6 Year Old**

*John T. Hansford, D.M.D.; Robert D. Kelsch, D.M.D.; Mauricio Wiltz, D.D.S.*

Radiolucencies of the jaws mostly are isolated findings associated with inflammatory processes and consistent with inflammatory periapical disease. Occasionally, larger lytic/radiolucent lesions are identified and though infrequent, may be multiple and concurrent. Case report explores pediatric patient with no known concomitant syndrome who presented with multiple intraoral swellings.

## **44 The Evolution and Fabrication of Implant-supported Full-arch Hybrid Prostheses From Conventional Casted Metal to an All-Ceramic Zirconia**

*Amanda Ouzer, D.M.D.*

Implant-supported, full-arch hybrid prostheses have developed from cast-metal frameworks with acrylic or porcelain to all-ceramic zirconia frameworks. The creation of CAD/CAM manufacturing has removed the inaccuracies seen with casting and made use of zirconia possible. An explanation of fabrication processes.

## **50 Herpes Zoster of the Third Division of the Trigeminal Nerve**

A Clinical Pathologic Conference

*Karen Doan, D.D.S.; Kenneth Stoler, D.D.S.; Keri Logan, D.M.D.*

Clinical case is presented to highlight the differential diagnosis and treatment modalities used to diagnose a challenging disease. Clinical pathologic conference is provided to outline appropriate courses of action in management of herpes zoster.



Use your smartphone to scan this QR Code and access the current online version of The New York State Dental Journal.

## Roadblocks to Licensure

*Today's dental school graduates, much as previous generations, face unnecessary hurdles in the form of licensing exams and restrictions on movement.*

I remember those two days very well. They were the most challenging days I had yet to face in my young dental career. After four years of dental school, I now had to pass my boards, or my future as a dentist would be in jeopardy. Talk about pressure. I wondered why the dental establishment and educational system put us through such a demanding process. After all, we had just endured four years of intense training. Wasn't that enough? Why did we have to prove our ability to anonymous dentists we had never seen before and probably would never see again? How would they interpret our work? Would we perform well enough to pass? We didn't know the answers to these questions, but that didn't matter. All that mattered was passing the exam to be eligible for licensure. So we did it.

Of course, passing this exam only allowed a narrow choice of states where we could qualify for licensure. At the time, freedom of movement in dentistry across the country was a contradiction in terms. There was no freedom of movement from state to state. Each state had its own rules and regulations governing licensure. Each state recognized only one or two regional board exams as evidence of competency to practice dentistry. If you hadn't taken and passed the exam required, you could not be licensed in that state—unlike medicine, which had true freedom of movement around the country. It didn't matter if you graduated at the

top of your dental class. If you had a bad day when you took the board, or your examiner had a bad day, you were locked out until you could pass the exam.

At the time I wondered why we had to go through this process. I felt if the dental school was doing its job properly, anyone graduating would be a capable dentist, trusted to do the right thing, who had the patient's best interest at heart and was competent to do the work well. What did an exam held under intense pressure in an artificial situation to an arbitrary standard of excellence prove? Not a lot, it seemed. I couldn't foresee private practice operating that way.

Also, I wondered how ethical it was to treat a patient for just one day and then say goodbye. No follow-up if the patient ran into trouble because of the restoration you placed. What about those patients? Who would take care of them if something unforeseen happened? I discovered later that these thoughts were shared by many others in the dental community. In fact, this seems to be a cause for every generation of dental school graduates.

Here in New York State, we have done something about this situation. We have PGY-1. In order to obtain a license, a dental graduate must now attend one year of postgraduate training in a residency program. This removes the ethical considerations of a two-day test. It removes the stress such a two-day, winner take all test creates. But it does

**NYS DJ****EDITOR**

Kevin J. Hanley, D.D.S.

**MANAGING EDITOR**

Mary Grates Stoll

**ADVERTISING MANAGER**

Jeanne DeGuire

**ART DIRECTORS**

Kathryn Sikule / Ed Stevens

**EDITORIAL REVIEW BOARD**

Frank C. Barnashuk, D.D.S.

David A. Behrman, D.M.D.

Michael R. Breault, D.D.S.

Ralph H. Epstein, D.D.S.

Daniel H. Flanders, D.D.S.

Joel M. Friedman, D.D.S.

Chester J. Gary, D.D.S., J.D.

G. Kirk Gleason, D.D.S.

John T. Grbic, D.M.D., M.S., MMSc.

Brian T. Kennedy, D.D.S.

Stanley M. Kerpel, D.D.S.

Elliott M. Moskowitz, D.D.S., M.Sd

Francis J. Murphy, D.D.S.

Eugene A. Pantera Jr., D.D.S.

Robert M. Peskin, D.D.S.

Georgios Romanos, D.D.S.,

D.M.D., Ph.D., Prof.Dr.med.dent

Robert E. Schifferle, D.D.S., MMSc., Ph.D.

**PRINTER**

Fort Orange Press, Albany

NYS DJ (ISSN 0028-7571) is published six times a year, in January, March, April, June/July, August/September and November, by the New York State Dental Association, 20 Corporate Woods Boulevard, Suite 602, Albany, NY 12211. In February, May, October and December, subscribers receive the NYSDA News. Periodicals postage paid at Albany, NY. Subscription rates \$25 per year to the members of the New York State Dental Association; rates for nonmembers: \$75 per year or \$12 per issue, U.S. and Canada; \$135 per year foreign or \$22 per issue. Postmaster: Please send change of address to the New York State Dental Association, Suite 602, 20 Corporate Woods Boulevard, Albany, NY 12211. Editorial and advertising offices are at Suite 602, 20 Corporate Woods Boulevard, Albany, NY 12211. Telephone (518) 465-0044. Fax (518) 465-3219. E-mail info@nysdental.org. Website www.nysdental.org. Microform and article copies are available through National Archive Publishing Co., 300 N. Zeebe Rd., Ann Arbor, MI 48106-1346.



not allow graduates to obtain a license in most other states. Only seven states recognize the PGY-1 pathway to licensure. If a graduate wants a license in a state that does not recognize PGY-1, he or she must take a board exam approved by that state. And now we are back to square one.

**Remedy at Hand**

There is a “test” that takes care of all this. It is called the curriculum integrated format (CIF). This test is given throughout the dental student’s career and involves the student’s own patients of record. It is not given in a two-day timeframe, where the pressure is ramped up. Rather, it is given during the normal sequence of treatment for a student’s patient. Dental school faculty is present, as are third-party testing proctors. Treatment proceeds normally for the patient and for the student. If something untoward occurs during the treatment, the student and dental faculty member remediate the emergency and the patient leaves with definitive treatment and a permanent restoration in place. This is better for the student and the patient.

A successful pilot program of the CIF was conducted recently at the University at Buffalo School of Dental Medicine. Not only did the students participating in the program find it much less stressful than a traditional board exam, they were also able to learn from the experience. If they failed a particular part of the test, it wasn’t the end of the world. They were able to retake that part as they continued their studies at the dental school. The patients were treated ethically, unlike in a typical board exam that uses live patients. In those cases, the student would have to remediate the failed portion of the exam at a later date, and the patient was left with a temporary fix for which they would have to seek care.

With the CIF, none of this occurs. The patient is remediated immediately and leaves with definitive treatment. The student learns from the experience and can retake the test at a later date as part of the normal educational experience. CIF allows for the student to satisfy an independent evaluation of performance by a third-party examiner and also satisfy educational requirements of the school. This

---

changes the nature of the experience for students, as they treat their own patients of record just as they would as part of the usual educational process. Nothing is taken out of context. And all treatment rendered would ordinarily be provided as part of their clinical experience.

The biggest concern graduating dental students have now is their unprecedented debt load—in the \$200,000 to \$300,000 range and more. The only way this debt can be paid is if the graduate can find meaningful employment following graduation. And they can only find employment if they can get licensed. We should make it as easy as possible for them to get a license. The CIF would allow them to do that.

### **End Restricted Movement**

The second biggest concern of dental students is freedom of movement around the country. Many states still do not recognize the various board exams given in different areas of the country. In order for students to practice in these states, they must take a board exam recognized by that state. There are only seven states that recognize PGY-1 as a pathway to licensure. Any student from

New York State who wants to practice elsewhere will be limited to those seven states if he or she doesn't want to take a state-recognized board exam. Again, he or she would be faced with performing in an artificial atmosphere under extremely stressful situations—not a good climate for success.

It's time we had universal reciprocity in this country. The demographics of dental practice are changing. The number of women practicing increases each year. If those women are married, and their spouses are not dentists, there is a likelihood the spouse could be transferred to another state. If that state does not recognize the credentials of the incoming dentist, she would have to take another board exam. This hardly seems fair. The CIF is a terrific way to accomplish universal reciprocity while maintaining the integrity and ethics of the profession. Medicine allows freedom of movement. It is time dentistry joined it in 21st century.

 D.D.S.





# What Mentorship Means to Me

*We all need to be open to the possibility that a student or resident will seek us out for guidance.*

Maria Maranga, D.D.S.

It was the morning of Saturday, April 5, 2014. I was in Chicago for the closing day of the ADA Membership and Recruitment Conference. I was exhausted after having spent several days there already, and I was counting down the final hours in my head. I saw several people staring at a computer screen, their mouths ajar. They signaled me to come over. I stared intently for a long second not absorbing what I was seeing. Then the words began to be processed in my head. Jiwon Lee, former leader of the American Student Dental Association and Columbia dental student, had been missing since the previous Tuesday.

Jiwon, a fourth-year dental student, an honorary member of my female mentorship group and my friend, could be gone. It was a difficult few weeks. But as they passed, we all still hoped she would be found safely. I recalled a conversation back in September when we were both speakers at an ASDA event in New York State. She asked me, “How do you do it all, all the time and with great energy?” I explained that even the most organized person can get unraveled juggling work, home, family and dental society obligations. One of the keys, I told her, is to marry the near-perfect spouse. She laughed, but I explained that a spouse who helps with household chores—cooking, children and laundry—is essential for your own well-being. “It’s your foundation, to which you look to with happiness when things aren’t so rosy,” I said. She then revealed that she felt overwhelmed and couldn’t imagine ever getting to the stage I had. I joked that all female dentists have doubts, but that there was no way that she, Jiwon Lee, would not succeed.

Fast forward to Sunday, May 4. It is confirmed that Jiwon Lee is dead. The morning is spent grieving through texts to both my male and female dental students, dental society folk and whoever else would listen. A memorial celebration of Jiwon is held on Monday, May 12. I contacted some of my students to offer to drive them to Columbia. I knew that the evening would be hard enough without worrying about getting there. Since our dental school is at least a two-hour ride away, I secured permission from the dean to take the students out of clinic early that day.

The funeral, although quite sad, was, in fact, a celebration of Jiwon’s short life. Several people told stories about time they had

shared with her, and her brother played video from her previous days as a standup comic in Manhattan. We were instructed by the family to take home the floral arrangements.

This is what mentorship means to me. It’s not just confined to the formal relationships we have with our student and residents. Anyone can be a mentee, and sometimes you don’t even realize that the person sees you as a mentor. Since Jiwon wasn’t a Stony Brook student, it never occurred to me that she thought of me as her mentor. This reinforces my belief that we must always think of ourselves as role models to our younger colleagues and act accordingly. We must be open to anyone who might seek us out. Mentor is not a title; it’s a way of life.

There’s no special formula for being a successful mentor, just the caring of one individual for another and another and then another. Sometimes we don’t seek to be a mentor; it just happens. At the moment, there are at least three to four endodontic recommendations that I still need to write, along with one dental school recommendation. It’s not a role for everyone. And although I take great joy and pride in those that I mentor, it can be hard.

However, just like guiding our own children and teaching them morals, values and religious beliefs, mentoring dental students instills a “high” that cannot be duplicated. Of course, there is an expression of gratitude after the mentoring process ends. And when those you mentored in turn seek out younger people to mentor, that too is rewarding. But if you’ve never thought about mentoring, please seek out a student. I promise you will not only get “hooked,” you will gain new insight into yourself. And that, my dear friends, will complete the circle of mentorship.

I hope you were mentored by a caring individual. And that you mentored and then observed your students begin the process over again. It’s similar to the circle of life. I encourage you to grab on and go for a ride! //

*Dr. Maranga, an endodontist who practices in Suffolk County, Long Island, is vice chair of the ADA Council on Membership. This Viewpoint is taken from an article she wrote last year for Incisal Edge, a magazine published by Benco Dental.*





# Contrasting Perspectives of Dental Faculty and Their Students Concerning Dental Academia

Ahmad Abdelkarim, D.D.S, M.S., Ph.D., Ed.D.; Donna Sullivan, Ph.D.

## ABSTRACT

**Attitudes of dental students and faculty towards research, faculty recruitment, new school openings, and academic career rewards and disadvantages were evaluated. Both groups believe that research should be discretionary. Faculty had significantly higher support for supervising and encouraging students to conduct research. Students favored recruitment of better quality (not more) faculty, and some displayed concerns about a tuition increase if additional faculty members were recruited. Both groups said there is no significant need for new dental schools. Faculty displayed a more favorable view toward an academic career and a significantly more favorable view of faculty recruitment.**

Several emerging trends are occurring in dental academia. These include increasing emphasis on research, faculty recruitment, new school openings and academic careers in general. Because students and faculty are critical to the dental field, assessing their opinions towards these trends is important. While attitudes of dental students have been widely measured, the perceptions of

dental faculty have been evaluated to a much lesser degree. This could be because the main target in dental education as a whole is the dental student rather than the faculty. As a consequence, the differences in attitudes towards academia between these two groups are unknown.

For example, faculty members who work full time in academia are typically satisfied with their positions. A study at University of Nebraska College of Dentistry found that most faculty members intend to remain in academia.<sup>1</sup> These full-time faculty members acknowledged professional relationships with colleagues and students as a positive factor. As expected, lack of resources (i.e., low salaries) was the most significant negative factor of the academic environment. Another study reported similar results regarding the advantages and disadvantages of an academic career. Specifically, the advantages cited were the desire to teach and conduct scholarly activities; the main disadvantage was lower income relative to private dental practice.<sup>2</sup>

Newly recruited faculty members report the work environment as the most important factor in considering and maintaining an academic position in dentistry.<sup>3</sup> Rogér et al. found that the most important factors in dental academia are mentorship and student interaction, job diversity, intellectual challenge, scholarship opportunities and satisfaction with the nature of the work.<sup>4</sup> Lifestyle and family compatibility, flexibility, lifelong learning and

professional duty are also advantages of academic careers. These factors encourage faculty to maintain an academic career.

In contrast, Rupp et al. found that dental students generally do not have enough knowledge to make an informed decision regarding a career in dental education.<sup>5</sup> In this study, surveys were obtained from 561 students from selected schools. This study showed that 71% of students had a self-reported “knowledge score” of “None” and “Low” with respect to 12 selected issues of academic dentistry, such as salary, benefits, faculty practice opportunities and promotion. This study demonstrates that students are simply unaware of the nature of an academic career in dentistry.<sup>5</sup>

Given the emerging trends in dental academia, the purpose of this mixed methods study was to investigate differences in the attitudes and perceptions of dental students and faculty members on topics that are crucial to the future of dental education.

## Methods

The research design for this mixed methods study aimed at collection of quantitative and qualitative data. To achieve this aim, a survey instrument was designed with nine statements intended to evaluate the level of agreement between students and faculty toward dental academia. This survey instrument was evaluated for content validity and validated through peer review with five faculty members with experience in survey development and pilot tested with five respondents. Faculty members and respondents were both given the chance to provide feedback on the wording, content and structure. Changes were made accordingly.

The survey was built electronically through SurveyMonkey.com (SurveyMonkey, Portland, OR). The survey required the respondent initially to self-identify as either a student or a faculty member. Before each survey, respondents were asked to indicate their level of agreement with the statements on a five-point Likert scale (i.e., 1: strongly agree to 5: strongly disagree). Table 1 presents the statements that were included in the surveys. An optional comment section was available to allow respondents to add further observations.

Before disseminating the survey, the Institutional Review Board of the University of Mississippi Medical Center reviewed and approved a request to conduct the study. Afterwards, invitations to participate were sent to 10 schools of dentistry in the United States, at Columbia University, Harvard University, Loma Linda University, University of California at Los Angeles, University of Florida, University of Louisville, University of Mississippi, Uni-

versity of Tennessee, University of Texas at Houston and Western University. These schools are located in different geographic areas. Participants were contacted via e-mail through their schools once. The e-mail provided the reason for the study and a link to the survey. Participation was voluntary and anonymous.

Statistical analyses were completed through IBM SPSS Statistics software for Windows, version 19.0 (IBM Corp., Armonk, NY). Mann-Whitney U test was used to investigate differences between students and faculty. The significance level ( $\alpha$ ) was set at 0.05. Qualitative data were exported from SurveyMonkey and collected into one Microsoft Word document. Codes for subthemes were created. The data was coded to detect common themes presented by students and faculty.

## Results

Four hundred and one students and 180 faculty members responded to the surveys (581 total respondents), an estimated response rate of 16%. A total of 247 comments were obtained in the comments sections.

Attitudes and perceptions of students and faculty toward dental academia by number and percentage are presented in Table 2. Additionally, themes and comments are presented in Table 3.

It was clear that students and faculty either agree or strongly agree that teaching dentistry effectively is a task that requires creativity, skills, communication and patience and that conducting research properly is a difficult task that calls for time, creativity, resources and talents.

Regarding research, students displayed an average neutral rating (2.82) and perceived this area to be dependent upon the student. Several commenters said students should not be encouraged to conduct research. A theme was found among students that not all students are interested in research and that research is not for everyone. Faculty had significantly higher agreement toward encouraging and supervising students to conduct research; however, several faculty respondents indicated they would mentor and supervise only students who are interested and capable

**TABLE 1**  
**Survey Statements Evaluating Attitudes and Perceptions of Dental Students and Faculty Toward Dental Academia**

1. Teaching dentistry effectively is a task that requires creativity, skills, communication and patience.
2. There is a significant need for new dental schools to create more dentists.
3. Dental faculty should supervise and encourage more students to conduct research.
4. Conducting research properly is a difficult task that requires time, creativity, resources and talents.
5. Dental schools should give more importance to research in their facilities.
6. Dental schools are better venues for research than manufacturers and practices.
7. More faculty members should be recruited and retained in dental schools.
8. The best way to recruit more faculty members is to increase their benefits (i.e., salary).
9. In the long run, an academic career is a more stable, fulfilling and secure option than private practice.

**TABLE 2****Attitudes and Perceptions of Students and Faculty toward Dental Academia by Number and Percentage to Each Statement****Statement showed similar ratings between students and faculty**

| Group  | 1 Strongly agree | 2 Agree   | 3 Neutral | 4 Disagree | 5 Strongly disagree | Average Rating | Standard Deviation | Z statistic | p-value |
|--|------------------|-----------|-----------|------------|---------------------|----------------|--------------------|-------------|---------|
| 1. Teaching dentistry effectively is a task that requires creativity, skills, communication and patience |                  |           |           |            |                     |                |                    |             |         |
| Students   | 262 (66%)        | 125 (32%) | 8 (2%)    | 1 (0%)     | 0 (0%)              | 1.36           | 0.54               | -1.460      | .144    |
| Faculty  | 129 (72%)        | 48 (27%)  | 2 (1%)    | 0 (0%)     | 0 (0%)              | 1.29           | 0.48               |             |         |

2. There is a significant need for new dental schools to create more dentists

|          |        |         |           |           |           |      |      |       |      |
|----------|--------|---------|-----------|-----------|-----------|------|------|-------|------|
| Students | 9 (2%) | 37 (9%) | 104 (26%) | 145 (36%) | 106 (26%) | 3.75 | 1.02 | -.505 | .613 |
| Faculty  | 3 (2%) | 10 (6%) | 48 (27%)  | 75 (42%)  | 44 (24%)  | 3.82 | 0.92 |       |      |

**Statements showed significantly different ratings between students and faculty**

| Group  | 1 Strongly agree | 2 Agree   | 3 Neutral | 4 Disagree | 5 Strongly disagree | Average Rating | Standard Deviation | Z statistic | p-value |
|--|------------------|-----------|-----------|------------|---------------------|----------------|--------------------|-------------|---------|
| 3. Dental faculty should supervise and encourage more students to conduct research |                  |           |           |            |                     |                |                    |             |         |
| Students   | 34 (9%)          | 113 (28%) | 158 (40%) | 75 (19%)   | 18 (5%)             | 2.82           | 0.98               | -5.699      | .000*   |
| Faculty  | 32 (18%)         | 76 (43%)  | 52 (29%)  | 17 (10%)   | 1 (1%)              | 2.32           | 0.90               |             |         |

4. Conducting research properly is a difficult task that requires time, creativity, resources and talents

|          |           |           |          |         |        |      |      |        |       |
|----------|-----------|-----------|----------|---------|--------|------|------|--------|-------|
| Students | 132 (33%) | 211 (53%) | 40 (10%) | 15 (4%) | 1 (0%) | 1.85 | 0.76 | -3.750 | .000* |
| Faculty  | 86 (48%)  | 82 (46%)  | 9 (5%)   | 2 (1%)  | 1 (1%) | 1.61 | 0.69 |        |       |

5. Dental schools should give more importance for research in their facilities

|          |          |           |           |          |         |      |      |        |       |
|----------|----------|-----------|-----------|----------|---------|------|------|--------|-------|
| Students | 33 (8%)  | 104 (26%) | 175 (44%) | 71 (18%) | 17 (4%) | 2.84 | 0.96 | -4.803 | .000* |
| Faculty  | 31 (17%) | 71 (40%)  | 50 (28%)  | 24 (13%) | 3 (2%)  | 2.42 | 0.98 |        |       |

6. Dental schools are better venues for research than manufacturers and practices

|          |          |           |           |          |        |      |      |        |       |
|----------|----------|-----------|-----------|----------|--------|------|------|--------|-------|
| Students | 68 (17%) | 146 (37%) | 127 (32%) | 49 (12%) | 8 (2%) | 2.45 | 0.98 | -4.775 | .000* |
| Faculty  | 54 (30%) | 78 (43%)  | 35 (19%)  | 11 (6%)  | 2 (1%) | 2.05 | 0.92 |        |       |

7. More faculty members should be recruited and retained in dental schools

|          |           |           |          |         |        |      |      |        |       |
|----------|-----------|-----------|----------|---------|--------|------|------|--------|-------|
| Students | 158 (40%) | 168 (42%) | 60 (15%) | 12 (3%) | 1 (0%) | 1.82 | 0.81 | -5.326 | .000* |
| Faculty  | 113 (64%) | 48 (27%)  | 14 (8%)  | 2 (1%)  | 0 (0%) | 1.46 | 0.69 |        |       |

8. The best way to recruit more faculty members is to increase their benefits and salary

|          |          |           |           |         |        |      |      |        |       |
|----------|----------|-----------|-----------|---------|--------|------|------|--------|-------|
| Students | 92 (23%) | 156 (39%) | 108 (27%) | 36 (9%) | 5 (1%) | 2.26 | 0.96 | -6.337 | .000* |
| Faculty  | 89 (50%) | 60 (34%)  | 13 (7%)   | 15 (8%) | 1 (1%) | 1.76 | 0.95 |        |       |

9. In the long run, an academic career is a more stable, fulfilling and secure option than private practice

|          |         |          |           |           |         |      |      |        |       |
|----------|---------|----------|-----------|-----------|---------|------|------|--------|-------|
| Students | 8 (2%)  | 45 (11%) | 172 (43%) | 137 (34%) | 37 (9%) | 3.38 | 0.88 | -3.286 | .001* |
| Faculty  | 12 (7%) | 37 (21%) | 69 (39%)  | 44 (25%)  | 16 (9%) | 3.08 | 1.04 |        |       |

\*  $p < 0.05$  Note: Percentages may not total 100% because of rounding



of conducting research. Several faculty members suggested that schools should give higher priority to clinical training than to research.

A majority of students (54%) agreed that dental schools are better venues for research than manufacturers and dental practices. A higher percentage (73%) of faculty agreed to this, but also said while research at dental schools reduces bias, good research can be conducted at any location.

Students believed that the recruitment of dental educators should be a matter of quality over quantity. Teaching dentistry effectively requires patience and skill, and the student respondents indicated they believe that not all dentists are suited to be professors. Students also felt that there is a shortage of faculty and lack of mentoring in dental schools. Increasing faculty benefits

as “the best way to recruit more faculty members” solicited moderate agreement from students (62%) and significantly higher agreement (84%) from faculty. Students’ comments revealed a consistent theme that increasing faculty salaries would increase students’ tuition, thus causing an increase in student debt. Several faculty members commented on a significant pay discrepancy between private practice and faculty salaries, making recruitment difficult. Several comments from faculty cited increasing salaries as a successful retention strategy.

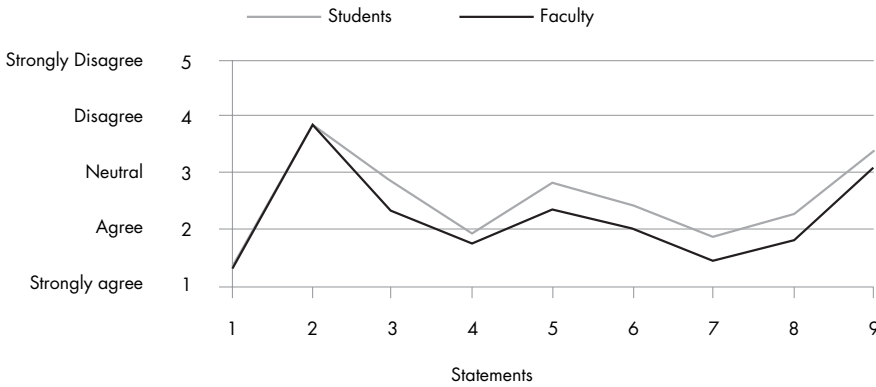
Students and faculty showed similar neutral-to-negative sentiments about opening new dental schools to train more dentists. The average ratings of students (3.75) and faculty (3.82) showed general disagreement with the need for new schools. Comments indicated that respondents felt that the number of dental schools

**TABLE 3**  
**Themes and Comments on Dental Academia: Summary of Qualitative Data**

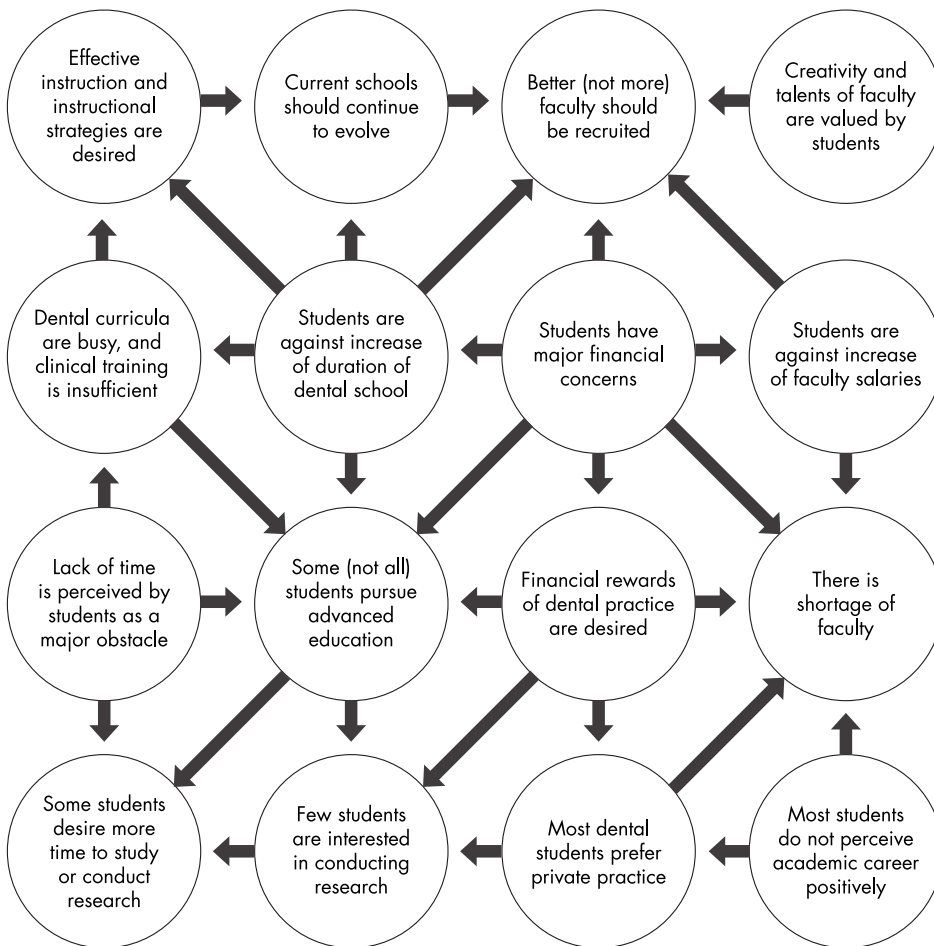
| Area of investigation                     | Themes and comments presented by students   | Themes and comments presented by faculty   |
|---|---|--|
| Research in dental schools                | <ul style="list-style-type: none"> <li>• Students should not be encouraged to conduct research. Not all students are interested in research.</li> <li>• Meaningful research takes significant amount of work and time.</li> <li>• Research should not be mandatory. Clinical training is more important.</li> <li>• Dental schools are likely better venues for research than manufacturers and practices because there is less bias.</li> </ul>  | <ul style="list-style-type: none"> <li>• Faculty should mentor and supervise students who are interested and capable of conducting research.</li> <li>• Conducting research takes time and is difficult.</li> <li>• Schools should give the opportunity for students to conduct research. It should be discretionary.</li> <li>• Dental schools are better venues than manufacturers and practices due to less bias.</li> </ul>                            |
| Faculty recruitment                       | <ul style="list-style-type: none"> <li>• Not all dentists are suited to be professors. Students have limited clinical experience, relative to professors.</li> <li>• There is a shortage of faculty and lack of mentoring in dental schools.</li> <li>• Recruitment of better quality (not more) faculty is necessary. Quality is more important than quantity.</li> <li>• Increasing faculty salaries would increase students’ tuition, causing increase in students’ debt.</li> </ul> | <ul style="list-style-type: none"> <li>• High quality and younger faculty members should be recruited. Those who desire to teach as a retirement home after selling practice should not be recruited.</li> <li>• There is a significant pay discrepancy between private practice and faculty salaries, causing recruitment difficulties.</li> <li>• Increasing faculty salaries is one way to retain good faculty, but is difficult to achieve.</li> </ul> |
| Opening new dental schools                | <ul style="list-style-type: none"> <li>• There is not a significant need for new dental schools.</li> <li>• The amount of dental school and dentists is sufficient.</li> <li>• There is no shortage of dentists. There are perhaps too many dentists. The problem is access to care.</li> <li>• There is a need to serve the underserved, not train more dentists.</li> </ul>   | <ul style="list-style-type: none"> <li>• Several dental schools opened recently, and eventually some will close.</li> <li>• There is a disparity in access to care, not lack of dentists.</li> <li>• Resources should be utilized in improving current schools, not creating new ones.</li> <li>• New dental schools are not encouraging academics and research.</li> </ul>  |
| Academic career rewards and disadvantages | <ul style="list-style-type: none"> <li>• An academic career may be fulfilling, but it is a personal preference.</li> <li>• An academic career is not for everyone.</li> <li>• An academic career does not seem to be rewarding financially, secure or stable.</li> </ul>  | <ul style="list-style-type: none"> <li>• An academic career is fulfilling for those who enjoy the rewards of teaching.</li> <li>• Choosing an academic career depends on the person’s life goals and preferences.</li> <li>• Stability and security of an academic career are debatable.</li> </ul>  |

and dentists is sufficient. Both groups believe there is no shortage of dentists and that the problem is access to care. Students added that there is a need to provide care for the underserved, rather than to educate more dentists.

**Figure 1.** Average Ratings of Students and Faculty of Statements



**Figure 2.** Causal Network of Students and Faculty Attitudes toward Dental Academia



## Discussion

Several important findings were discovered in this survey. Notably, academic work was perceived as demanding. Teaching dentistry was considered a task that requires creativity, skill, communication and patience, and conducting research properly was perceived to be a difficult task that requires time, creativity, resources and talents.

These findings were further reinforced by student and faculty ratings and comments to other related statements. For example, several students' comments stated the desire for better (not more) faculty. Furthermore, students perceived time to be a major issue for conducting meaningful research. Students believe that research or teaching is not for everyone. In fact, it appears that research is supported more by faculty than students, but they both agreed that clinical training should be the main goal of the dental school. This is consistent with the findings of Cardall et al. that dental students value education and clinical experiences in the dental school much more than research.<sup>6</sup>

The findings on faculty recruitment were significant. Although 82% of students thought more faculty members should be recruited and retained in dental schools, several expressed concerns about tuition increases. Also, students did not believe that an academic career would be financially rewarding, secure or stable. Some faculty members view the stability and security of an academic career as debatable. In the current study, the faculty's average rating was neutral (3.08) toward the argument that "an academic career is a more stable, fulfilling and secure option than private practice." In previous, different studies, however, faculty members were typically satisfied with their positions, with the lack of resources (i.e., low salaries) being the most significant negative factor of the academic environment.<sup>1</sup>

Rupp et al. had argued that students are "simply unaware of the nature of an academic career in dentistry."<sup>5</sup> The findings of this study also suggest that students are unaware of academic career rewards, advantages and disadvantages. Therefore, their perception toward an academic career may significantly

---

differ from faculty perceptions. It is also clear from the present study that the recruitment of excellent faculty members is highly desirable and would lead to better mentoring, enhanced student clinical training and would improve students' learning experiences.

One faculty respondent advised that younger faculty members should be recruited to meet the dental program needs. Another faculty member suggested that those who desire to teach as a way to retire after actively practicing should not be recruited. It should be remembered, however, that these older faculty members possess the experience that younger faculty members do not possess. Therefore, a balance in the faculty body should be maintained by the inclusion of members of diverse educational and experience backgrounds.

Finally, neither group found a significant need for new dental schools to train more dentists. They considered the number of dentists to be sufficient. The need for new dental schools was not generally supported in this study.

### Conclusions


This study revealed several differences between students and faculty attitudes towards dental academia. Responses on seven out of

nine statements showed statistical differences. Figure 1 displays the average ratings of both groups towards the survey statements. The first two statements generated virtually identical ratings by students and faculty. However, the other seven statements generated statistically different ratings, which do not appear to be divergent or opposites but rather slightly different (i.e., slightly more agreement or disagreement of one group over the other).

Both groups express the importance of the recruitment of excellent faculty members. Based on the findings of this study, causal networks were created and presented in Figure 2. This figure demonstrates that recruitment of excellent faculty members is essential.

Several students expressed concerns about the recruitment of more faculty members. The major concern is financial. In fact, students' financial concerns seem to have an impact on several issues that were discovered in this survey, as outlined in Figure 2, of causal network. It was reported that several faculty have awareness of students' financial concerns.<sup>7</sup>

It also appears that the recruitment of better rather than more faculty members is interconnected with several areas, such as enhancement of students' clinical abilities, implementation



of effective instruction, elimination of the need for more faculty members, and enhanced overall learning experiences of students who appreciate talented and competent faculty members. Faculty members are aware that students feel that the clinical experience they are receiving is deteriorating.<sup>7</sup>

Faculty recruitment should be limited only for selected dentists who enjoy the rewards of teaching, and should continue to consider young and talented faculty members in addition to experienced or highly credentialed members. Increasing faculty salaries and benefits would certainly improve retention. Finally, as with the need for better (not more) faculty members, there is a need to continually enhance existing schools of dentistry before creating new ones.

It is important to evaluate students and faculty attitudes and perceptions of academia in other disciplines, such as medicine, nursing and pharmacy. In fact, the evaluation of students and faculty attitudes and perceptions of any discipline would be valuable. //

*The authors thank all dental schools and respondents who participated in this survey. Queries about this article can be sent to Dr. Abdelkarim at [aabdelkarim@umc.edu](mailto:aabdelkarim@umc.edu).*

## REFERENCES

1. Froeschle ML, Sinkford JC. Full-time dental faculty perceptions of satisfaction with the academic work environment. *J Dent Educ* 2009;73(10):1153-70.
2. Schenkein HA, Best AM. Factors considered by new faculty in their decision to choose careers in academic dentistry. *J Dent Educ* 2001;65(9):832-40.
3. Shepherd KR, Nihill P, Botto RW, McCarthy MW. Factors influencing pursuit and satisfaction of academic dentistry careers: perceptions of new dental educators. *J Dent Educ* 2001;65(9):841-8.
4. Rogér JM, Wehmeyer MM, Milliner MS. Reflections on academic careers by current dental school faculty. *J Dent Educ* 2008;72(4):448-57.
5. Rupp JK, Jones DL, Seale NS. Dental students' knowledge about careers in academic dentistry. *J Dent Educ* 2006;70(10):1051-60.
6. Cardall WR, Rowan RC, Bay C. Dental education from the students' perspective: curriculum and climate. *J Dent Educ* 2008;72(5):600-9.
7. Abdelkarim A, Benghuzzi H, Hamadain E, Tucci M, Ford T, Sullivan D. U.S. dental students' and faculty members' attitudes about technology, instructional strategies, student diversity, and school duration: a comparative study. *J Dent Educ* 2014;78(4): 614-21.



Dr. Abdelkarim



Dr. Sullivan

**Ahmad Abdelkarim, D.D.S., M.S., Ph.D., Ed.D.**, is an associate professor and chair, Department of Orthodontics, University of Mississippi School of Dentistry, Jackson, MS.

**Donna Sullivan, Ph.D.**, is a professor, Department of Medicine, University of Mississippi School of Medicine, Jackson, MS.

# Risk Factors in the Development of Oral Bisphosphonate-induced Osteonecrosis

Stacey Reiss, D.D.S.; Daniel Sultan, D.D.S.

## ABSTRACT

**Bisphosphonates (BPs) are routinely prescribed to prevent pathologic fractures in osteoporotic patients. Bisphosphonate-associated osteonecrosis of the jaw (BRONJ) is a rare, but serious complication, most often following extraction in patients treated with intravenous BPs. We report a case of BRONJ in a patient following six years of oral BP administration for the management of osteoporosis, complicated by four years of prednisone therapy for pulmonary fibrosis. This rare presentation led us to investigate other causative factors, in particular, glucocorticoids. This report aims to construct a clinically relevant predictive model of the disease through better understanding of concomitant risk factors.**

Bisphosphonates (BPs) are commonly used to prevent pathologic fractures in patients with osteoporosis and other diseases that cause loss of bone mass, such as Paget's disease, bone metastases and multiple myeloma.<sup>1,2</sup> Oral BPs are the preferred pharmacological agent given to osteoporotic patients. They are prescribed to 73% of the osteoporotic patients who make 6.3 million yearly

medical visits.<sup>3</sup> BPs are effective in increasing bone mineral density, lowering the risk of fractures, controlling bone pain and in preventing the pathologic fractures often associated with metastatic bone cancers.<sup>4,5</sup>

Bisphosphonates are categorized as either non-nitrogenous or nitrogenous. The simple non-nitrogenous BPs cause the induction of osteoclast apoptosis after they are metabolically incorporated into nonhydrolyzable analogues of adenosine triphosphate that accumulate intracellularly in osteoclasts.<sup>6</sup> By contrast, the more potent nitrogen-bisphosphonates inhibit farnesyl pyrophosphate synthase, an enzyme in the apoptotic pathway. Accordingly, nitrogenous BPs are used to manage metastatic cancer in bone (intravenous zoledronic acid or pamidronate) or for the prevention and treatment of osteoporosis (oral alendronate, risedronate, ibandronate). They are also used for the treatment of Paget's disease (intravenous pamidronate and oral alendronate or risedronate) and for the short-term management of acute hypercalcemia (intravenous zoledronic acid or pamidronate).<sup>6</sup>

Until recently, the only significant adverse events were associated with the more potent nitrogen-containing BPs and included upper gastrointestinal intolerance and an acute phase reaction with fever and flu-like symptoms.<sup>7</sup> However, in 2003, the first cases of BRONJ were reported by Marx et al.<sup>8</sup> in association with zoledronic acid and pamidronate. According to the Association of Oral and Maxillofacial Surgeons, patients may be considered



to have BRONJ if the following three characteristics are present: current or previous treatment with BPs; exposed bone in the maxillofacial region that has persisted for more than eight weeks; and no history of radiation therapy to the jaw.<sup>1</sup>

BRONJ is now an accepted complication of BP treatment. Affected patients are typically medically compromised, over 55, present following dental extractions or oral trauma, and are being medicated with the more potent nitrogen-containing BPs for the treatment of non-osteoporotic bone disease.<sup>5</sup>

Most oral lesions develop in the posterior lingual mandible near the mylohyoid ridge. Furthermore, 60% of cases occur after dental extraction or other dentoalveolar surgery.<sup>9</sup> More cases of BRONJ occur in females than in males, probably because breast cancer patients are often on IV BPs for the management of their bone metastases. Because postmenopausal osteoporosis is an indication for BP use, this segment of the female population is also at risk for BRONJ.<sup>2</sup>

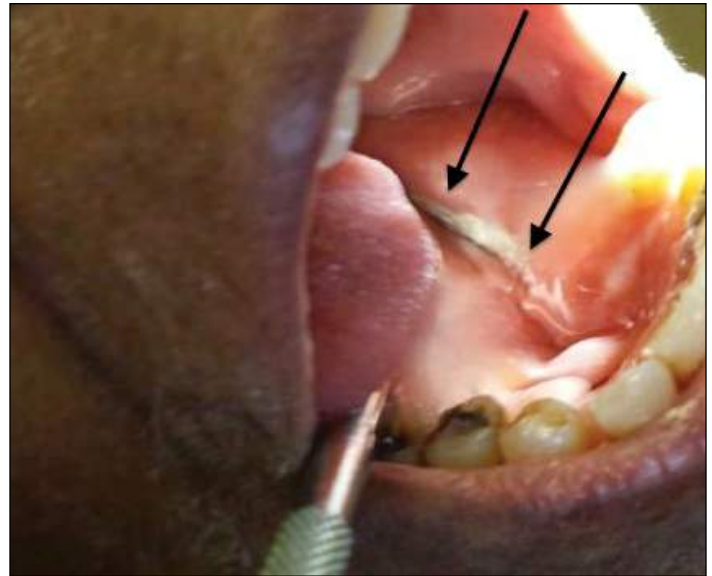
A compromised blood supply to the maxilla and mandible, along with altered bone remodeling after exposure to long-term BP therapy, has been proposed as the theory behind the pathogenesis of osteonecrosis.<sup>2</sup> When dental extractions are performed for this group of patients, the open extraction wound in the maxilla or mandible has a compromised healing ability that does not always cope with the presence of oral microflora, especially if the patient's innate or acquired immunity is suppressed.<sup>2</sup> The bone becomes infected and necrotic. Osteonecrosis is found exclusively in the jaw and not in any other bone in the body despite the systemic actions of BPs. It is believed that the limited vascularity of the jaw, as well as its frequent remodeling due to masticatory use, may explain this unique incidence of osteonecrosis in the jaws.<sup>1</sup>

### Case Report

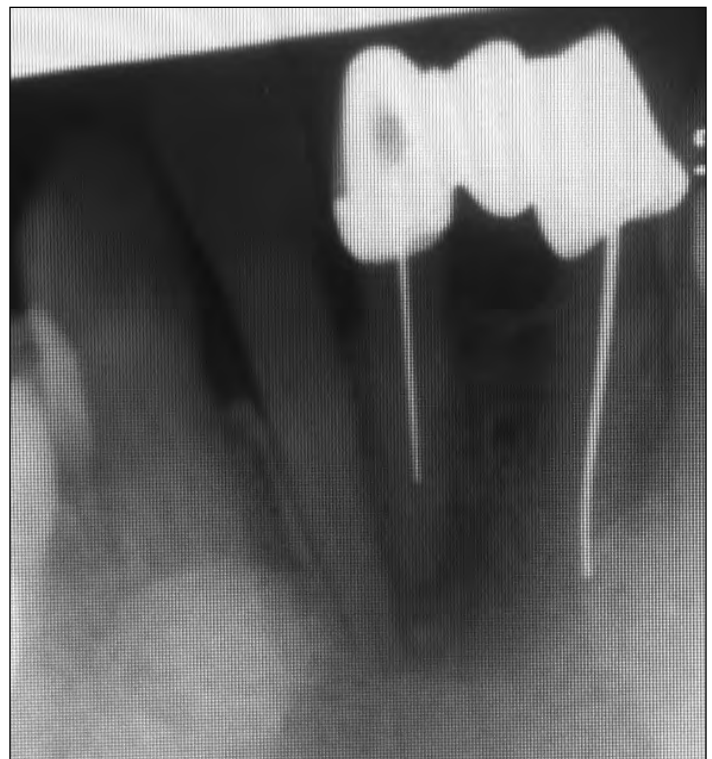An 87-year-old female patient was seen in the emergency clinic of the College of Dental Medicine in November 2013 with the complaint, "I have an abscess." The patient's medical history was significant for the presence of pulmonary fibrosis, which was being managed with 10 mg of prednisone daily for four years.

Examination revealed a buccal gingival abscess adjacent to tooth #25. An area of exposed bone, measuring approximately 54 mm x 8 mm, was incidentally observed along the left mylohyoid ridge (Figure 1). The patient said the area of bone exposure developed two years ago, shortly after a dental extraction and that it was painful when touched. The periapical radiograph revealed a lucency apical to tooth #25, with possible involvement of tooth #26 (Figure 2). A panoramic radiograph was obtained (Figure 3).

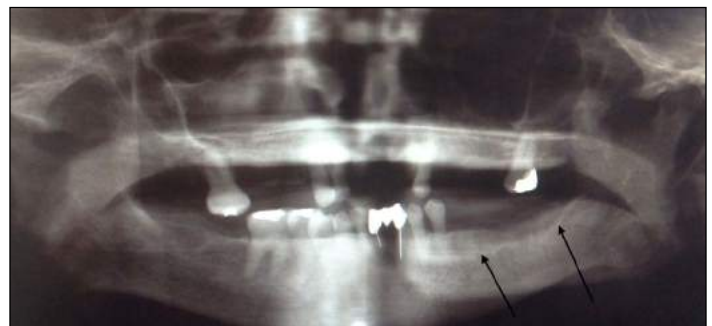Questioning indicated she had been taking an oral BP, Actonel (risedronate), for six years following a diagnosis of osteoporosis. The patient was told that the lesion in her left posterior mandible was a complication of a dental extraction that resulted from her prolonged use of BPs and that extraction of teeth #25 and



**Figure 1.** Clinical presentation of exposed necrotic bone, left mandibular mylohyoid ridge.



**Figure 2.** Periapical radiolucency noted on radiograph apical to tooth #25.



**Figure 3.** Panoramic radiograph shows erosion of lingual cortical plate.

#26 was not indicated because of the increased risk of BRONJ. She was advised that the best course of action would be to have root canal therapy, and a referral was made.

## Discussion

Assessing the true incidence and prevalence of BRONJ is difficult because of variables such as type, dosage and duration of the BP treatment, and patient variables that include the status of the disease, age, other complicating diseases and other prescribed medications. It is important to differentiate between cases of BRONJ associated with patients receiving intravenous BPs and those receiving oral BPs. The risk of BRONJ associated with oral BP therapy for osteoporosis seems to be very low, estimated between 1 in 10,000 patient-treatment years and 1 in 100,000 patient-treatment years.<sup>9</sup> The risk of BRONJ in patients who are being treated with high doses of intravenous BPs is clearly greater, in the range of 1-10 per 100 patients.<sup>9</sup> Of the 368 cases of documented BRONJ reviewed by Woo et al.,<sup>10</sup> 354 (96.2%) had received high-dose IV bisphosphonates for multiple myeloma, metastatic breast cancer, prostate cancer, Paget's disease or other metastatic diseases. By contrast, only 14 (3.8%) had received oral BPs for osteoporosis (13 oral alendronate, 1 oral risedronate).

These figures are fairly consistent with reports from the U.S. pharmaceutical industry. Merck Inc. has received reports of 170 cases of BRONJ associated with oral alendronate therapy out of approximately 20 million patient-years, or 0.7 reports of BRONJ per 100,000 patient-years of exposure.<sup>11,12</sup> With oral risedronate, 1 to 1.2 cases per 10,000 patient years were reported by Procter & Gamble.<sup>12</sup> Within randomized controlled trials of BPs used to treat osteoporosis, no cases of BRONJ were reported out of >17,000 patients exposed to alendronate, > 44,000 patient-years

of exposure to therapy with risedronate or > 12,000 patients who were exposed to oral ibandronate.<sup>12</sup>

In a large randomized control trial of 7,714 postmenopausal women who had received either intravenous zoledronic acid or a placebo, only two potential cases of BRONJ were found. One woman had received zoledronic acid and one had received the placebo. Although the authors admit that incidence estimates might be inaccurate when the number of cases is small, even more troubling is the development of BRONJ in the placebo patient. This suggests that BRONJ does not only occur in patients who take BPs. There may be other causative factors.<sup>13</sup> Recently, other pharmacologic agents have been implicated in the development of osteonecrosis, such as antiresorptive (Denosumab) and antiangiogenic therapies, leading to the proposal of the more inclusive terminology of MRONJ (medication-related osteonecrosis of the jaw).<sup>14</sup>

Although various risk factors and co-morbidities for the development of BRONJ have been proposed, few have been fully elucidated. Increased duration of BP therapy is the best supported risk factor for both IV and oral BP administration. The prevalence of osteonecrosis increases over time, from a near 0 at baseline to 0.21% after four or more years of oral BP exposure.<sup>14</sup> Dentures were associated with a mild increase of osteonecrosis (odds ratio 4.9).<sup>15</sup> Pre-existing periodontal disease is another well-recognized risk factor, found in 50% of the cases.<sup>16</sup> Tobacco use and co-morbid conditions such as anemia and diabetes have been inconsistently reported as risk factors.<sup>14,15</sup>

Using a homogeneous population of 120 multiple myeloma patients with an identical regimen of IV pamidronate (90 mg/month), Jadu et al.<sup>17</sup> explored the frequency of BRONJ, as well as its risk factors and co-morbidities. The statistically significant risk factors for the development of bone necrosis were:

duration of pamidronate exposure; dental extraction; cyclophosphamide, prednisone, erythropoietin treatment; anemia; renal dialysis; and age (Table 1). After trauma, prednisone therapy demonstrated the greatest association out of the variables analyzed, which is in agreement with other published studies.<sup>18,19</sup> Although the details regarding the precise mechanism behind the development of osteonecrosis remain unclear, similar to bisphosphonates, glucocorticoid therapy can negatively affect wound healing, infection, bone turnover and angiogenesis.<sup>10,13</sup> The overlapping effects of bisphosphonates and glucocorticoids may act synergistically, contributing to a higher risk for the pathogenesis of osteonecrosis of the jaw.

**Table 1**<sup>17</sup> Statistically Significant Risk Factors Associated with ONJ

| Variable  | Odds Ratio | 95% CI     | P value |
|---|------------|------------|---------|
| Duration of pamidronate exposure (years) <sup>a</sup> | 1.7        | 1.35-2.15  | <0.001  |
| Dental extraction                                     | 5.3        | 2.05-13.68 | <0.001  |
| Cyclophosphamide therapy (metronomic doses)           | 3.4        | 1.22-9.28  | 0.019   |
| Prednisone therapy                                    | 6.5        | 1.44-29.47 | 0.014   |
| Erythropoietin therapy                                | 3.9        | 1.47-10.17 | 0.006   |
| Low hemoglobin level <sup>b</sup>                     | 6.8        | 2.15-21.61 | 0.001   |
| Renal dialysis  | 3.2        | 1.23-8.25  | 0.006   |
| Age (years) <sup>c</sup>                              | 1.1        | 1.04-1.15  | 0.001   |

<sup>a</sup> Each additional year of pamidronate therapy increased the risk by 1.7 times.

<sup>b</sup> Low hemoglobin level was defined as less than the median, which was 121 g/l.

<sup>c</sup> Each additional year of life increased the risk by 1.1 times.

CI, confidence interval.

## Conclusion

Prednisone, used in our patient for her pulmonary fibrosis, may have acted synergistically with risedronate to compromise the blood supply to bone, which, in turn, led to bone necrosis. Corticosteroids can cause avascular necrosis of bone through a variety of mechanisms, including hypercoagulability and fat emboli of small blood vessels, which leads to the mechanical obstruction of blood flow.<sup>18-19</sup> The increased duration of BP use, combined with the concurrent dosages of prednisone, may demonstrate a complex interaction of factors that put our patient at higher risk for the development of BRONJ, even though her BP was orally administered. It is hoped that documentation of this case report will prompt research to further investigate the association of these and other medications. ❧

*The authors thank Louis Mandel, D.D.S., associate dean, clinical professor, Division of Oral and Maxillofacial Surgery, Columbia University College of Dental Medicine, New York, NY, for his assistance in the writing of this article.*

## REFERENCES

1. Bhuyan R, et al. Bisphosphonate-induced osteonecrosis. *J Oral Maxillofacial Pathol* 2013;17(3):460-462.
2. Gupta S, et al. Bisphosphonate related osteonecrosis of the jaw. *Natl J Maxillofacial Surg* 2013;Jul 4(2):151-158.
3. Stafford RS, Drieling RL, Hersh AL. National trends in osteoporosis visits and osteoporosis treatment. *Arch Intern Med* 2004;164:1525-1530.
4. Delmas PD, Recker RR, Chesnut CH III, et al. Daily and intermittent oral ibandronate normalize bone turnover and provide significant reduction in vertebral fracture risk: Results from the BONE study. *Osteoporosis Int* 2004;15:792-798.
5. Cheng A, et al. The dental implications of bisphosphonates and bone disease. *Australian Dent J Medications Supplement* 2005;50:4-13.
6. Roelofs AJ, Thompson K, Gordon S, Rogers MJ. Molecular mechanisms of action of bisphosphonates: current status. *Clin Cancer Res* 2006;12:62225-62305.
7. Bilezikian JP. Osteonecrosis of the jaw—do bisphosphonates pose a risk? *N Engl J Med* 2006;355:2278-2281.
8. Marx RE. Pamidronate (Aredia) and zoledronate (Zometa) induced avascular necrosis of the jaws: a growing epidemic. *J Oral Maxillofac Surg* 2003;61:1115-1117.
9. Khosla S, Burr D, Cauley J, et al, for the American Society for Bone and Mineral Research. Bisphosphonate-associated osteonecrosis of the jaw: report of a task force of the American Society for Bone and Mineral Research. *J Bone Miner Res* 2007;22:1479-1491.
10. Woo SB, Hellstein JW, Kalmar JR. Systematic review: bisphosphonates and osteonecrosis of the jaws. *Annals of Internal Medicine* 2006;144(10):753-761.
11. American Dental Association Council on Scientific Affairs. Dental management of patients receiving oral bisphosphonate therapy: expert panel recommendations. *J Am Dent Assoc* 2006;137:1144-1150.
12. Silverman S. Osteonecrosis of the jaw and role of bisphosphonates: a critical review. *Am J Med* 2009;122(2A):33-45.
13. Grbic JT, Landesberg R, Lin S-Q, for the Health Outcomes and Reduced Incidence with Zoledronic Acid Once Yearly Pivotal Fracture Trial Research Group. Incidence of osteonecrosis of the jaw in women with postmenopausal osteoporosis in the Health Outcomes and Reduced Incidence with Zoledronic Acid Once Yearly Pivotal Fracture Trial. *J Am Dent Assoc* 2008;139:32-40.
14. Ruggiero SL, Dodson TB, Fantasia J, et al. American Association of Oral and Maxillofacial Surgeons position paper on medication-related osteonecrosis of the jaws—2014 update.
15. Kyrgidis A, Vahtsevanos K, Koloutsos G, et al. Bisphosphonate-related osteonecrosis of the jaws: a case-control study of risk factors in breast cancer patients. *J Clin Oncol* 2008;26:4634.
16. Tsao C, Darby I, Ebeling PR, et al. Oral health risk factors for bisphosphonate-associated jaw osteonecrosis. *J Oral Maxillofac Surg* 2013;71:1360.

17. Jadu F, Lee L, Pharoah M, Reece D, Wang L. A retrospective study assessing the incidence, risk factors and comorbidities of pamidronate-related necrosis of the jaws in multiple myeloma patients. *Ann Oncol* 2007; 18:2015-9.
18. Durie B, Katz M, McCoy J, Crowley J. Osteonecrosis of the jaws in myeloma: time dependent correlation with Aredia and Zometa use. *Blood* 2004;104:756.
19. Saad F, Brown JE, Van Poznak C, et al. Incidence, risk factors, and outcomes of osteonecrosis of the jaw: integrated analysis from three blinded active-controlled phase III trials in cancer patients with bone metastases. *Ann Oncol* 2012;23:1341.



Dr. Reiss



Dr. Sultan

**Stacy Reiss, D.D.S.**, is a resident in orthodontics at the University of Connecticut School of Dental Medicine, Farmington, CT.

**Daniel Sultan, D.D.S.**, is an oral/maxillofacial surgery resident at Long Island Jewish Medical Center, New Hyde Park, NY.

# Occlusal Characteristics of the Primary Dentition Revisited

Stanley A. Alexander, D.M.D.; Marjan Askari, D.M.D., M.S.; Patricia Lewis, D.D.S., M.P.H.†

## ABSTRACT

**The occlusal characteristics of the primary dentition of 130 children 3 to 6 years old were examined. Variables were the terminal plane relationship, primary canine occlusion, spacing, overjet and overbite relationships. The flush terminal plane was the most common finding. A Class I relationship of the primary canine occurred in 85% of the subjects. Spaced dentitions occurred 81% of the time, while the presence of primate spaces occurred in at least one of the four quadrants. The overjet relationship varied from +1 mm to 4 mm in all subjects, and the majority of children were considered to have a normal overbite.**

The occlusion of the permanent dentition is largely influenced by specific characteristics of the primary dentition. These include the terminal plane relationship, the primary canine relationship, spacing versus non-spacing, the degree of overbite and the degree of overjet. These observations were originally discussed by Baume<sup>1</sup> in 1950, Arya, Savara, and Thomas<sup>2</sup> in 1973, and modified by Bishara and co-workers<sup>3</sup> in 1988 on Iowa children.

Contradictory findings have been reported in the literature when different populations and ethnic groups are examined for

these characteristics<sup>4-12</sup> within the primary dentition. The most prevalent occlusal molar relationship within the United States varies from flush terminal plane to mesial step,<sup>1,3,12</sup> while in Israeli children, the flush terminal plane was reported to be 2.4-times more frequent than the mesial step occlusion.<sup>13</sup> In a recent study of 1,836 children from Chennai, India, it was reported that the flush terminal plane is the most common arrangement.<sup>14</sup> In Saudi children as well, the flush terminal plane represented the majority type of relationship observed.<sup>9</sup> Conversely, the prevalence of the mesial step occlusion was observed in 47.7% of Jordanian children, followed by flush terminal plane at 37% and distal step in 3.7% of the 3- to 6-year-old children examined.<sup>11</sup>

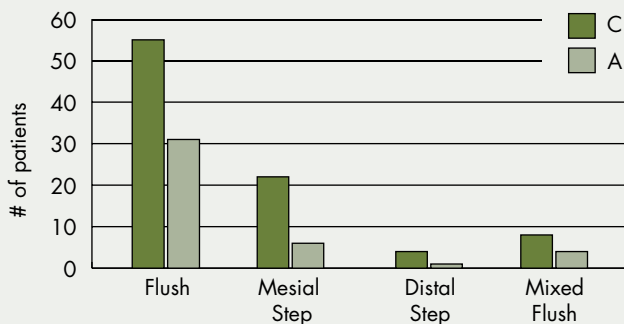
Considering the variety of information available relative to the terminal plane relationships of the primary dentition and other aspects of the occlusion of multiple regional and ethnic groups,<sup>4,9-11,15</sup> the present study aimed to evaluate and revisit these occlusal features in children from Long Island, New York.

## Materials and Methods

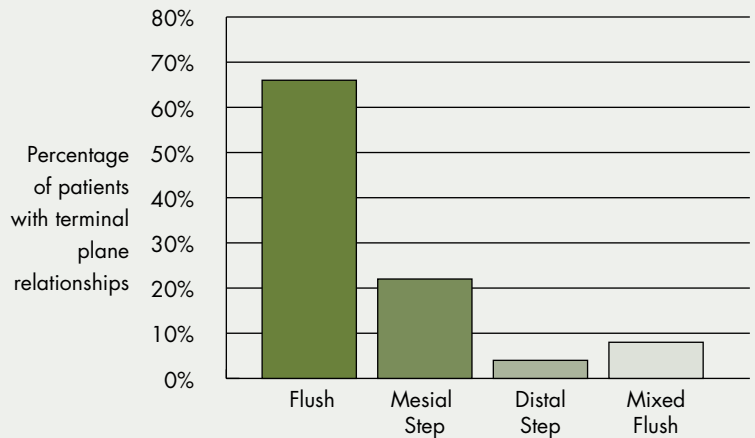
The patients examined in this study lived in communities on Long Island and were obtained from the University Clinic at Stony Brook University. They gave consent as private patients to participate. Approval was also granted by the Stony Brook Internal Review Board on

† Deceased





**Figure 1.** Prevalence of terminal plane relationships of primary second molars in Caucasian and Asian children. Statistically significant difference ( $p < 0.05$ ) was observed for frequency of terminal plane relationships and subgroup for both ethnicities, respectively. Legend: C= Caucasian; A= Asian



**Figure 2.** Prevalence of terminal plane relationships of primary second molars. Statistically significant difference ( $p < 0.01$ ) was observed between flush, mesial step, distal step and mixed flush subgroup terminal plane.

the Use of Human Subjects. Data was acquired by the first and third authors, who performed the clinical examination, photographs and study models. Direct observations were carried out on the study models for the terminal plane relationships and by visual examination for the canine relationship, spacing, overjet and overbite. All measurements were made with a steel millimeter ruler. Second measurements were repeated by each examiner within five minutes of the initial measurements and averaged when appropriate.

The original patient pool consisted of 173 consecutively examined patients, ages 3 to 6. Twenty-seven patients did not meet the inclusion criteria. The sample size of Hispanics and African-Americans was extremely small (16 patients) and not sufficient for a cross-sectional study; therefore, they were removed from the analysis, which resulted in a total patient sample of 130 preschool children ranging in age from 3 to 6—72 females and 58 males. Racial distribution showed 68% Caucasian and 32% Asian (Chinese, Japanese, Korean) individuals.

Inclusion criteria consisted of:

- Signed informed consent form
- Age of patients, 3-6 years
- Presence of all 20 deciduous teeth with unerupted permanent teeth
- No sucking or finger habits
- Absence of proximal carious lesions or interproximal restorations

Evaluation criteria consisted of:

#### 1. Terminal plane relationship

- Flush terminal plane: The distal surfaces of maxillary and mandibular primary second molars lie in the same vertical plane in centric occlusion.
- Mesial step: The distal surface of the mandibular primary second molar is mesial to that of the maxillary primary second molar in centric occlusion.
- Distal step: The distal surface of the mandibular second molar is distal to the distal surface of the maxillary primary second molar in centric occlusion.
- In the determination of the primary second molar relationship, if one side ends with a flush terminal plane and the other side ends with a mesial or distal step, the patient was classified as mixed flush subgroup. If one side of the patient was a mesial step and the other side a distal step, the patient was classified as mixed mesial subgroup.

#### 2. Primary canine relationship

- Class I: The cusp tip of the maxillary primary canine is in the same vertical plane as the distal surface of the mandibular primary canine.
- Class II: The cusp tip of the maxillary primary canine is mesial to the distal surface of the mandibular primary canine.
- Class III: The cusp tip of the maxillary primary canine is distal to the distal surface of the mandibular primary canine.



- 
3. Spaced (Type I dentition) or Non-spaced (Type II dentition).
  4. Presence of primate space in at least one quadrant, or absence of primate spaces.
  5. The degree of overjet: The amount of overjet was measured from the lingual surface of the most protruded maxillary primary incisor to the facial surface of the mandibular primary incisor recorded in millimeters.
  6. The degree of overbite: Normal, when the maxillary primary central incisor covered less than 50% of the mandibular primary central incisor in centric occlusion; increased when the maxillary primary central incisor covered more than 50% of the mandibular primary central incisor in centric occlusion; edge to edge when the maxillary and mandibular central incisors were edge to edge in centric occlusion; anterior open bite when there is no overlap or contact between the maxillary and mandibular central incisors.

#### **Statistical Analysis**


Data were collected and entered using the Statistical Package for Social Sciences (*SPSS version 15*). Frequency distribution was used for the descriptive analysis. A Pearson's chi-square test was used

to compare the different occlusal characteristics between the different ethnicities and age groups. For all tests, a p-value of 0.05 or less was considered to be of statistical significance. To determine intra- and interobserver reliability, the intraclass correlation coefficient for absolute agreement was calculated.

#### **Results**

The intraclass correlation coefficient revealed good repeatability for all intraoral and extraoral measurements. The mean value for all intraoral measurements was .950 (range .845-.985) for intraobserver repeatability and .930 (range .815-.970) for interobserver repeatability, respectively. Classification of the terminal plane relationship was in 100% agreement.

Figure 1 displays the racial data gathered from the study. Fifty-five Caucasians and 31 Asians displayed flush terminal plane relationships, while the mesial step appeared in 22 Caucasians and 6 Asians, respectively. As expected, few distal step occlusions were observed, with only four whites and one Asian demonstrating this form of occlusion. Seven Caucasians and four Asians displayed a mixed flush terminal plane subgroup where one side of the occlusion was flush and the opposite side was mesial step. No com-



bination of flush and distal step was observed. No mixed mesial terminal planes were observed. A statistically significant difference was observed ( $p < 0.05$ ) for both the Caucasian group and the Asian group when the prevalence of the flush terminal plane was compared to the mesial step, distal step and subgroup, respectively.

Figure 2 shows the frequency of the three types and subgroups of terminal plane relationships found in this study. Of the 130 children examined, 66% (86 patients) exhibited a flush terminal plane relationship. The mesial step relationship was found in 22% of the children (28 patients), while the distal step was the least common relationship observed (5 patients) in the symmetric relationships and appeared 4% of the time. The mixed flush subgroup was observed in 8% of the population studied (11 patients). A statistically significant relationship ( $p < 0.01$ ) was observed between the terminal plane relationship of the three group types—flush, mesial step and distal step—and the mixed flush subgroup.

The most common primary canine relationship was Class I, which was observed 85% of the time, followed by a Class II bilateral relationship (6%), Class II unilateral relationship (5%) and, finally, a Class III relationship (4%). The Class II bilateral canine occlusion appeared in all patients with a distal step occlusion. Of the 11 patients who showed a mixed flush terminal plane, the Class II canine occlusion always occurred on the side of the dentition that had a flush terminal plane molar relationship. No mesial step occlusions displayed a Class II canine relationship. The Class III canine relationship was observed in only the mesial step occlusion. A statistically significant difference ( $p < 0.01$ ) was demonstrated between the classes.

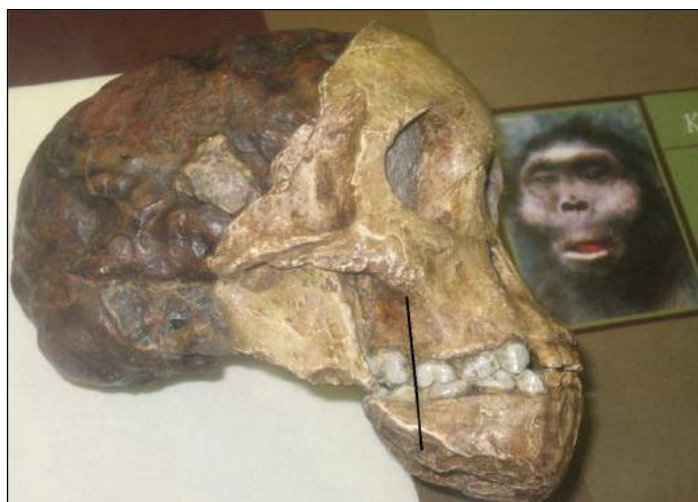The Type I dentition was observed 77% of the time, while the Type II dentition was observed in 23% of the children. This finding was statistically significant ( $p < 0.05$ ). One to four primate spaces occurred in all 130 children.

No child demonstrated a negative or zero overjet. Fifty-eight percent displayed overjets ranging from +1 mm to +2 mm, while 42% displayed overjets greater than 2 mm. The majority of children (65%) had a normal overbite, while 22% of children displayed an increased overbite, respectively. An edge-to-edge overbite relationship existed in 13% of the children. There was a statistically significant difference between the types of overbite recorded. An open bite tendency, as represented by the edge-to-edge

**TABLE I**  
**Occlusal Relationship of Primary Dentition in 3- 6-Year-Old Caucasian and Asian Patients**

| <b>Canine Relationship</b>                |                          |                           |                |              |
|---|--------------------------|---------------------------|----------------|--------------|
| Class I (85%)                             | Class II, bilateral (6%) | Class II, unilateral (5%) | Class III (4%) | Significance |
| 111                                       | 8                        | 6                         | 5              | $p < 0.01^*$ |
| <b>Spaced versus Non-Spaced Dentition</b> |                          |                           |                |              |
| Type I (spaced)                           | Type II (non-spaced)     | Primate Spaces            |                |              |
| 100 (77%)                                 | 30 (23%)                 | 130 (100%)                |                | $p < 0.05^*$ |
| <b>Degree of Overjet</b>                  |                          |                           |                |              |
| 0mm to -2mm                               | +1 mm to +2mm            | >+2mm to +4mm             |                |              |
| 0%  | 76 (58%)                 | 54 (42%)                  |                | ns           |
| <b>Degree of Overbite</b>                 |                          |                           |                |              |
| Normal                                    | Increased                | Edge to Edge              |                |              |
| 85 (65%)                                  | 28 (22%)                 | 17 (13%)                  |                | $p < 0.05^*$ |

\*indicates statistical significance



**Figure 3.** Fossilized skull of juvenile *Australopithecus africanus* specimen at American Museum of Natural History (New York), Bernard and Anne Spitzer Hall of Human Origins. Note erupting first permanent molars into end-on occlusal relationship as result of flush terminal plane of second primary molars.

relationship, was the least frequently observed overbite relationship (Table I).

### Discussion

Terminal plane relationships and primate spaces have been well documented in paleo-anthropological specimens.<sup>17</sup> Despite differences in tooth wear, food culture and diet of this fossilized skull of a *Australopithecus africanus* child (Figure 3), when compared to a modern child, the flush terminal plane and erupting permanent molars appear to be in a cusp-to-cusp position before the transition to Class I will be achieved. The modern human condition shows little difference between this early

---

ancestor and the development of contemporary occlusion. The relevance of the terminal relationship is a major parameter, in addition to the leeway space, for the establishment of first permanent molar occlusion.

Baume, in 1950,<sup>1</sup> in a longitudinal study, originally described the prevalence of the different terminal plane relationships in 30 California preschool children. His findings in order of highest prevalence was the flush terminal plane (86%), followed by mesial step (23%) and, finally, by distal step (less than 1%).

His findings remained unchallenged until Bishara's longitudinal study of Iowa school children.<sup>3</sup> In this study of 121, 5-year-old Iowa children, the distribution of the terminal plane relationships indicated a predominance of mesial step occlusions occurring 61% of the time, followed by flush terminal plane at 29% and distal step at 10%. These differences exhibited by Bishara may be due to the sample of patients, which was taken from the Iowa Longitudinal Growth Study and represented a regional population unlike Baume's California population.

Our findings, although provincial as well and smaller in prevalence of flush terminal plane occlusions than those reported by Baume,<sup>1</sup> are consistent with the results of several other previous studies that examined the primary occlusion.<sup>4,6,9,10</sup> The order of prevalence is flush terminal plane, followed by mesial step and, finally, distal step. A low prevalence of asymmetric terminal plane relationships was also noted, which is consistent with a recent study,<sup>14</sup> and directly related to the low frequency of subdivision malocclusions seen in the permanent dentition. Some reports have indicated a shift in the terminal plane relationship from flush to mesial step as the child's age increases from 3 to 5 years,<sup>15</sup> while the work of others<sup>1,16</sup> indicates that the pattern of the terminal plane arrangement remains unchanged from ages 3 to 6. Other reports indicate a decrease of the distal step occlusion from 3 to 5 years<sup>4,9,10,17</sup> due to a combination of mesial migration of the lower arch and growth of the mandible, although Baume<sup>1</sup> showed no such decrease in prevalence of the distal step occlusion.

Because of the population sample, the majority of children were represented by Caucasian and Asian populations. Despite the higher prevalence of Class III occlusions in an Asian population, and an anticipated increase in a mesial step occlusion, the flush terminal plane relationship was the dominant pattern within the Asian group, as well as in the Caucasian group, followed by mesial step and distal step, respectively. The small sample size of the Hispanic and African-American children removed from the study will require a greater subject population to accurately infer the predominant terminal plane arrangement for these ethnicities. However, it has been reported that the mesial step occlusion is the norm for African-Americans.<sup>12</sup>

The most common canine relationship observed was Class I (85%), which is comparable to other reports,<sup>6,9,10</sup> followed by Class II bilateral (6%), Class II unilateral (5%) and Class III (4%), respectively. In the present study, the low number of Class II canine occlusions found when compared to other reports<sup>15,18</sup> was most likely the result of the population group studied and the inclusion criteria, which eliminated any child with a finger or tongue habit that was capable of protruding the maxillary dentition. Similarly, the low frequency of Class III canine occlusions was presumably due to the prevalence of the flush terminal plane relationship, thus making the Class I canine occlusion and flush terminal plane important criteria for the establishment of a normal permanent dentition to develop. The flush arrangement of the primary molar relationship makes a Class III canine position nearly impossible if no other circumstances, such as atypical spacing or uncommon tooth size relationships, which involve tooth position, are active.

The prevalence of spacing (Type I occlusion) occurred in 77% of the individuals studied. This was in agreement with Baume<sup>1</sup> but much higher than other contemporary reports,<sup>10,18</sup> which revealed a spaced primary dentition in a range of 32% to 50%. The presence of primate spaces is a common finding in the primary dentition. All 130 children displayed primate spaces in at least one quadrant of their dentition, a number much higher than reported elsewhere<sup>1,10,11,15,18</sup> in American, Indian, African, Jordanian and Israeli children. Observations of primate spaces in all four quadrants or present only unilaterally have ranged from a low of 4%<sup>9</sup> to a high of 86%<sup>13</sup> prior to our report. The range of values for the presence or absence of primate spaces is most likely due to the specific population and time period studied.

The majority of children (58%) had an overjet in the normal +1 mm to +2 mm range. This finding was in accordance with other reports.<sup>9,10</sup> There was no finding of an anterior crossbite.

A normal overbite relationship was observed in 63% of children in the study, which is consistent with other reports.<sup>9-11</sup> Measurement of maxillary and mandibular vertical skeletal changes was not determined, since the study did not include initial or serial cephalograms because of the ages of the children studied.

## Conclusions

In the sample of patients examined, the flush or straight terminal plane relationship appeared to be the most common in the 3- to 6-year old age group (66%), followed by the mesial step (22%), and distal step (4%), respectively. There was a low prevalence of asymmetric primary molar relationships (8%).

The most common primary canine relationship was Class I, followed by Class II and Class III.

A Type I (spaced) primary dentition was observed in 77% of the children examined, while primate spaces appeared in at least one quadrant of all 130 children examined.

The majority of children had a normal overjet (58%) and overbite relationship (63%).

Queries about this article can be sent to Dr. Alexander at stanalexander427@gmail.com.

## REFERENCES

1. Baume LJ. Physiological tooth migration and its significance for the development of occlusion: I. The biogenetic course of the deciduous dentition. *J Dent Res* 1950;29:123-32.
2. Arya BS, Savara BS, Thomas DR. Prediction of first molar occlusion. *Am J Orthod* 1973; 63: 610-621.
3. Bishara SE, Hoppens BJ, Jakobsen JR, Kohout FJ. Changes in the molar relationship between the deciduous and permanent dentitions: a longitudinal study. *Am J Orthod Dentofacial Orthop* 1988;93:19-28.
4. Infante PF. Malocclusion in the deciduous dentition in white, black, and Apache Indian children. *Angle Ortho* 1975;45:213-18.
5. Nanda RS, Khan I, Anand R. Age changes in the occlusal pattern of deciduous dentition. *J Dent Res* 1973;52:221-24.
6. Ravn JJ. Occlusion in the primary dentition in 3-year-old children. *Scand J Dent Res* 1975;83:123-30.
7. Valente A, Mussolino ZM. Frequency of overjet, overbite and open bite in the deciduous dentition. *Rev Odontol UnivSao Paulo* 1989;3:402-07.
8. Kabue MM, Moracha JK, Ng'ang'a PM. Malocclusion in children aged 3-6 years in Nairobi, Kenya. *East Afr Med J* 1995;72:210-20.
9. Farsi NM, Salam FS. Characteristics of primary dentition occlusion in a group of Saudi children. *Int J Paediatr Dent* 1996;6:253-59.
10. Otuyemi OD, Sote EO, Isiekwe MC, Jones SP. Occlusal relationships and spacing or crowding of teeth in the dentitions of 3-4-year-old Nigerian children. *Int J Paediatr Dent* 1997;7:155-60.
11. Abu Alhajja ES, Qudeimat MA. Occlusion and tooth/arch dimensions in the primary dentition of preschool Jordanian children. *Int J Paediatr Dent* 2003;13:230-39.
12. Anderson AA. Occlusal development in children of African American descent. Types of terminal plane relationships in the primary dentition. *Angle Orthod* 2006;76:817-23.
13. Kaufman A, Koyumdjisky E. Normal occlusal patterns in the deciduous dentition in preschool children in Israel. *J Dent Res* 1967;46:478-82.
14. Anitha XL, Asokan S. Occlusion characteristics of preschoolers in Chennai: a cross-sectional study. *J Dent Child* 2013;80:62-66.
15. Ferreira RI, Barreira AK, Soares CD, Alves AC. Prevalence of normal occlusion traits in deciduous dentition. *Pesqui Odontol Bras* 2001;15:23-28.
16. Hejde S, Panwa S, Bolar DR, Sanghavi MB. Characteristics of occlusion in primary dentition of preschool children of Udaipur, India. *Eur J Dent* 2012;6:51-55.
17. Wallace JA. Molar occlusion in the ape-man (*Australopithecus*). *Am J Orthod* 1973;63: 606-609.
18. Prado BN, Magalhaes LNC, Ferreira RI, Scavone-Junior H. Study of terminal plane relationships of the second molars in the deciduous dentition. *Rev Odontol Univers Cidade Sao Paulo* 2007;19:6-12.
19. Baidas L. Occlusion characteristics of primary dentition by age in a sample of Saudi preschool children. *Pakistan Oral Dent* 2010;30:425-431.
20. Bahadure RN, Thosar N, Gaikwad R. Occlusal traits of deciduous dentition of preschool children of Indian children. *Contem Clin Dent* 2012;3:443-447.



Dr. Alexander



Dr. Askari

**Stanley A. Alexander, D.M.D.**, is distinguished teaching professor emeritus, Department of Orthodontics & Pediatric Dentistry, Stony Brook University, Stony Brook, NY.

**Marjan Askari, D.M.D., M.S.**, is director of orthodontics, Holyoke Health Center, Holyoke, MA.

**Patricia Lewis, D.D.S., M.P.H.**, was assistant professor, Department of Orthodontics & Pediatric Dentistry, Stony Brook University, Stony Brook, NY.

# Multiple Radiolucencies of the Jaws in a 6 Year Old

John T. Hansford, D.M.D.; Robert D. Kelsch, D.M.D.; Mauricio Wiltz, D.D.S.

---

## ABSTRACT

**Radiolucencies of the jaws are a common finding. Mostly, they are isolated findings associated with inflammatory processes and consistent with inflammatory periapical disease, such as periapical cysts and periapical granulomas. If associated with the crowns of unerupted teeth, they may represent dentigerous cysts. However, occasionally, larger lytic/radiolucent lesions are identified; even more infrequently, these radiographic findings may be multiple and concurrent. The purpose of this report is to present the case of a 6-year-old female patient with no known concomitant syndrome who presented with multiple intraoral swellings and to discuss the treatment of multiple, bilateral mandibular and maxillary radiolucencies.**

Radiolucencies of the jaws are routinely found in pediatric and adolescent populations. Most often they are isolated findings associated with inflammatory processes and consistent with inflammatory periapical disease.<sup>1</sup> When associated with the crowns of unerupted teeth, they may represent dentigerous cysts. On occasion these lesions may be larger than usual and, upon radio-

graphic examination, multiple and concomitant. When multiple concurrent radiolucencies of the jaws are noted, the differential diagnosis expands beyond routine odontogenic inflammatory cysts or dentigerous cysts to include odontogenic tumors, underlying systemic diseases, genetic syndromes and malignancy.<sup>8,10</sup>

The case presented here is of a 6-year-old girl who presented for evaluation with multiple radiolucencies of the jaws and associated soft-tissue swellings.

## Case Report

A 6-year, 8-month-old female presented to the Department of Pediatric Dentistry at Montefiore Medical Center in November of 2011. The chief complaint was of diffuse pain in the mouth over a period of three weeks, with a self-reported occurrence of “blood in the mouth” within days of presenting to the clinic. In response to the bleeding episode, the patient had presented to the emergency department, where she was referred to the pediatric dentistry clinic. Medical history was significant for mild, intermittent asthma and no known drug allergies. Any other underlying medical conditions were denied. Family history was noncontributory.

Extraorally, the patient appeared to be well developed, well nourished and of stated age. She had no gross facial swelling or facial asymmetry, and cranial nerves remained grossly intact; however, upon intraoral examination, multiple fluctuant swellings, each approximately 2.0 cm x 1.0 cm x 1.0 cm were identified



on palpation in the vestibules of each quadrant of the maxilla and mandible. Additionally, an “eruption cyst” was noted at the site of the permanent maxillary right central incisor. Further clinical findings included a mobile primary mandibular right canine; no other teeth exhibited mobility.

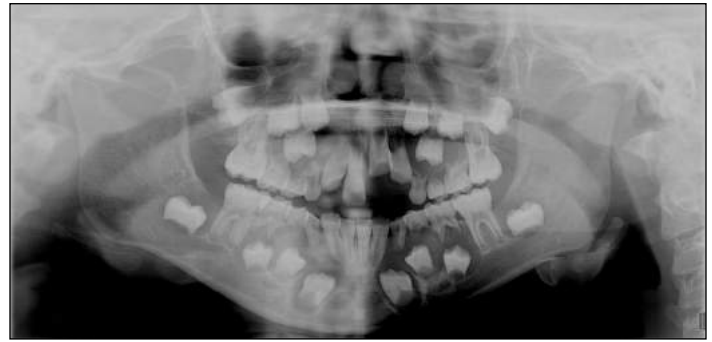A panograph (Figure 1) was obtained which revealed multiple bilateral radiolucencies associated with the crowns of the unerupted permanent dentition, specifically, the premolars and canines of both arches. The department of oral and maxillofacial surgery (OMFS) was consulted and surgery was scheduled to extract all primary canines except the primary maxillary right canine and primary first molars, with biopsy of the pericoronal soft tissues on Dec. 2, 2011. During surgery, the indicated teeth were extracted and the cysts were decompressed by way of incisional biopsies. Normal healing was observed at follow-up appointments with OMFS and pediatric dentistry after the extractions (Figure 2).

The tissue provided for histological examination revealed that each sample was a dentigerous cyst (Figure 3). Each of the cystic processes were lined by a thin squamous epithelial lining, with no inflammation in the cyst wall and demarcated by a fibrous connective tissue capsule.

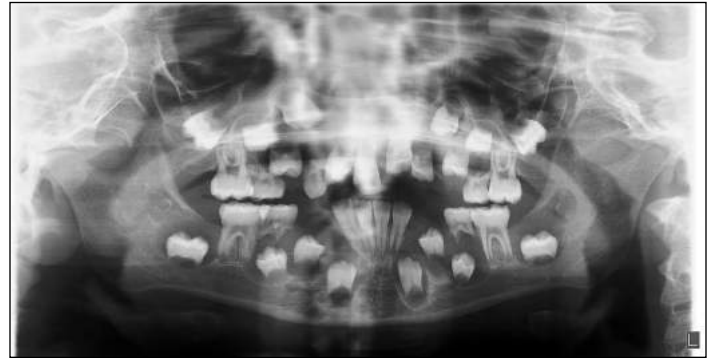At a subsequent periodic oral examination appointment in April 2012, when the patient was 7 years and 11 months old, premature eruption of the permanent premolars was observed. The roots of the premolars were minimally developed. OMFS was again consulted and placement of a physiological splint to improve retention of the first premolars was planned. A follow-up panograph (Figure 4) taken that day revealed expansion of the follicles associated with the mandibular second premolars and second molars. Bilateral space maintainers with composite buttons to splint the premolars were placed three weeks later.

The patient is following up with the pediatric dentistry and oral surgery departments at Montefiore and has begun orthodontic therapy. Extraoral photos and panographs taken in August of 2013 (Figures 5, 6) show normal healing and retention of the permanent dentition. The decompression of the cysts and extraction of the primary canines, with the exception of the primary maxillary right canine and primary first molars, was successful and the succedaneous teeth erupted and were retained. Histopathologic analysis of sample tissue resulted in a diagnosis of dentigerous cyst similar to the histopathology of the previously biopsied lesions.

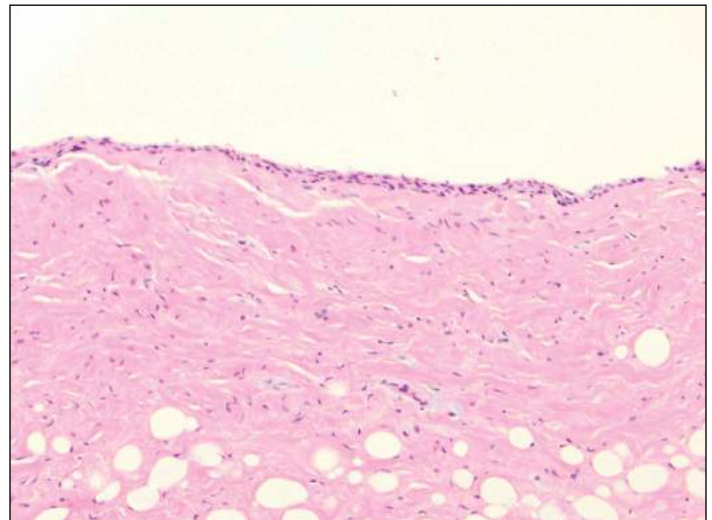
Within three months, the succedaneous teeth erupted. The splinting of the newly erupted teeth was also successful in stabilizing the teeth until further root development occurred. The second premolars upon follow up after surgery displayed radiographic lesions similar to those that had been operated on. The patient did not have additional surgery and the second premolars erupted without incident. As of 3/16/14, the patient had had recurrence of radiographic lesions around the permanent second



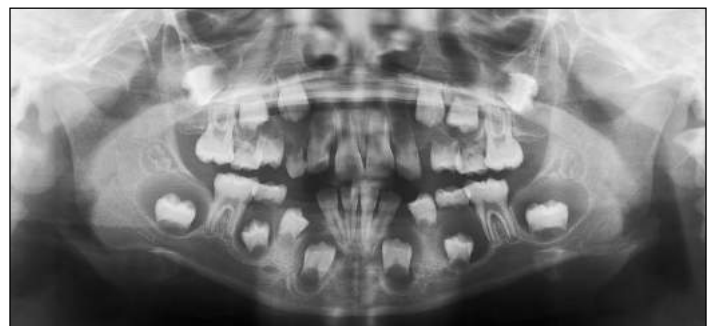
**Figure 1.** Preop pan (11-25-2011): Multiple radiolucencies involving unerupted crowns of canines and premolars in each arch.



**Figure 2.** FU pan (12-9-2011); Follow-up radiograph after extraction of primary teeth.



**Figure 3.** Histological evidence of dentigerous cyst lined by thin squamous epithelium without notable inflammatory filtration in fibrous connective tissue wall.

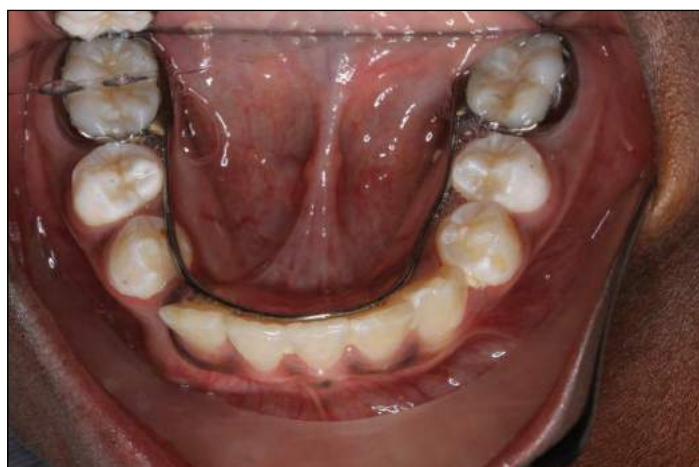

**Figure 4.** Bilateral radiolucencies associated with second molars and second premolars, along with premature eruption of mandibular first premolars.

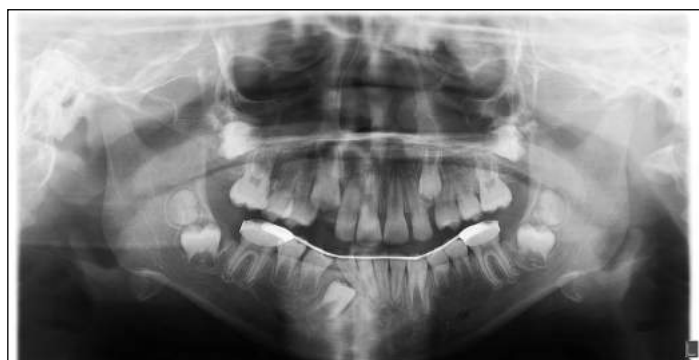molars in both arches (Figure 7). The orthodontic department in coordination with the OMFS department planned to enucleate the cysts involved with the second molars and remove the maxillary and mandibular third molars.

### Discussion

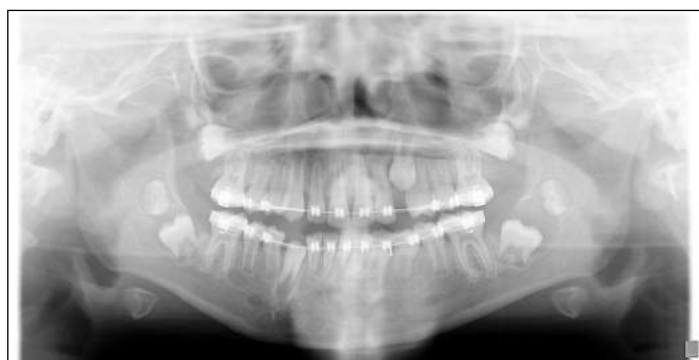This case presents an interesting discussion of multiple radiolucent lesions in a child. Biopsy of the lesions in this patient indi-



**Figure 5.** Clinical observation of eruption and retention of mandibular permanent dentition.



**Figure 6.** Panoramic radiograph, depicting eruption of teeth, resolution of cysts and root formation process.



**Figure 7.** Radiographic evidence of cysts associated with second molars.

cated that all of the lesions were dentigerous cysts. Although dentigerous cysts are the most common developmental odontogenic cysts, accounting for a quarter of the cysts affecting the jaws, they are rarely encountered bilaterally<sup>1</sup> and rarely seen in both arches at multiple loci in non-syndromic patients.<sup>13</sup> They are also seen more often in males than females.<sup>1,8</sup> And they are most frequently identified on radiographic examination as a solitary radiolucency associated with unerupted third molars and maxillary canines.

Radiographically, a dentigerous cyst presents as a well-circumscribed radiolucency associated with the crown of an unerupted permanent tooth; the border of the cyst is described as continuous with the cemento-enamel junction (CEJ) of the tooth.<sup>1,2</sup> The cyst is continuous with the crown of the tooth because fluid builds between the tooth and a residual layer of specialized epithelial components of the enamel organ, the inner enamel epithelium, stellate reticulum and outer enamel epithelium that were active during amelogenesis and collapse into a thin membrane of two to three cells of thickness, termed the reduced enamel epithelium.<sup>10</sup> Therefore, a dentigerous cyst includes the crown of the associated tooth in the lumen of the cyst, and the tooth's roots reside outside of the cyst.

The dentigerous cyst increases in size, occasionally displacing the associated tooth and adjacent teeth as fluid accumulates in the space between the crown of the unerupted tooth and the reduced enamel epithelium. Several mechanisms have been described to account for the bone resorption and expansion of the lesion. Basically, it appears that collagenases lead to bone degeneration by modifying collagen<sup>9</sup> and that collagenase has a role in altering cyst connective tissue capsules.<sup>6</sup> Additionally, prostaglandins and other mediators are involved in the metabolism of arachidonic acid and are known to induce bone resorption. Prostaglandin-2 is produced in dental cysts, as well as Interleukin-1,<sup>7</sup> a prostaglandin-2 stimulator, and both play a role in the subsequent osteoclastic bone resorption.<sup>4</sup> This may lead to a clinically observable swelling or fluctuance in the oral cavity, although most are identified as incidental findings on a radiograph.

Due to clinically and/or radiographically similar presentations related to pathologies, such as odontogenic keratocysts (keratocystic odontogenic tumor, World Health Organization designation) and unicystic ameloblastomas, a definitive diagnosis of dentigerous cyst cannot be obtained from clinical and radiographic evaluation alone; therefore, microscopic examination is imperative.

Radiographically, the observed radiolucencies were well defined, corticated lesions. These characteristics are seen in dentigerous cysts and odontogenic keratocysts; however, both generally occur as solitary findings and the patient seen in this report had lesions in all quadrants. The presence of multiple cysts, if they are odontogenic keratocysts, is considered indicative of nevoid basal cell carcinoma syndrome (Gorlin-Goltz syndrome).<sup>10</sup> However,

the patient did not display any of the other manifestations of this syndrome, such as bifid ribs; nevoid basal cell carcinomas; calcification of the falx cerebri; multiple, small epidermoid cysts; or frontal bossing.

Other conditions that present with multiple radiolucent lesions include Langerhans cell histiocytosis; however, no other organ systems or bones were involved, no discomfort was noted by the patient, and the typical radiographic findings noted around and beneath tooth roots was not consistent. Radiolucencies of the jaw are also observed in neurofibromatosis; however, no cutaneous café au lait macules or Lisch nodules (pigmented iris hamartomas), which are the major defining features of neurofibromatosis, were noted in this patient.<sup>15</sup> Nor was there a reported familial inheritance pattern.

The radiographic findings in this patient are consistent with the radiographic findings of patients with cherubism, but there was no enlargement of the jaws or deterioration of the facial aesthetic balance, which are characteristic of the disease.<sup>16</sup>

## Conclusions

Dentigerous cysts occur most frequently in males during the third decade of life as a solitary finding.<sup>1,8</sup> This circumstance of a 6-year-old female patient presenting with multiple dentigerous cysts in each quadrant is uncommon, especially without a concomitant syndrome.<sup>13</sup> And it raises concern about underlying medical conditions that may present in a similar fashion. Clinical and radiographic evaluation, along with an appropriate medical history, was important in determining a differential diagnosis. And histopathologic analysis was essential in determining a definitive diagnosis of dentigerous cyst. This case emphasizes the need for the dentist to be aware of the possible diagnoses related to intraoral swellings and radiographic radiolucencies and to appropriately treat and/or refer the patient.

With regard to the cysts associated with the second premolars and second molars, it is hypothesized that the osmotic pressure within the cysts associated with the second premolars was reduced at the time of primary tooth extraction and that decompression occurred over time. Initially, it was believed that the cysts associated with the second molars were decompressed either when the cyst made contact with the distal of the first molar or during lower lingual holding arch placement. The cysts associated with the second molars are now considered in need of surgical treatment. ✎

*The authors thank Nuntiya Kakanantadilok, D.M.D., for assistance in the preparation of this manuscript. Queries about this article can be sent to Dr. Hansford at johnt.hansford@gmail.com.*

## REFERENCES

1. Krishna Prasad L, Srinivas Chakravarthi P, Sridhar M, Ramakumar Y, Kattimani V. Nonsyndromic bilateral maxillary and unilateral mandibular multiple dentigerous cysts in a young girl: report of a rare case. *Int J Clin Pediatric Dent* 2010;3:219-223.

2. Kemal, Yamalik, et al. Nonsyndromic bilateral mandibular dentigerous cysts: report of a rare case. *Turkiye Klinikleri J Dental Sci* 2007;13:129-34.
3. Gayarathi R, Aparna D, Singh KD, Nagarajappa R. Dentigerous cyst involving multiple teeth in nonsyndromic patients and cholesterol granuloma: a review. *Int J Oral and Maxillofac Pathol* 2010;1:13-16.
4. Harris M, Jenkins MV, Bennett A, Wills MR. Prostaglandin and bone resorption by dental cysts. *Nature* 1973;245:213-214.
5. Harris M, Toller P. Pathogenesis of dental cyst. *Br Med Bull* 1975;31:159-163.
6. Harvey W, Guat-Chen F, Gordon S, Meghji S, Evans A, Harris S. Evidence for fibroblast as the major source of prostacyclin and prostaglandin synthesis in dental cysts in man. *Arch Oral Bio* 1984;29:223-9.
7. Meghji S, Harvey W, Harris M. Interleukin 1-like activity in cystic lesion of jaw. *Brit J Oral Maxillofac Surg* 1989;27:1-11.
8. Daley TD, Wysocki GP. The small dentigerous cyst: a diagnostic dilemma. *Oral Surg Oral Med Oral Pathol* 1995;79:77-8.
9. Sakamoto S, Sakamoto M, Goldhaber P, Glimcher M. Collagenase and bone resorption: isolation of collagenase from culture medium containing serum after simulation of bone resorption by addition by parathyroid hormone extract. *Biochem Biophys Res Commun* 1975;60:172-8.
10. Sapp J. Cysts of the oral regions. In: Sapp J, Eversole L, Wysocki G, eds. *Contemporary Oral and Maxillofacial Pathology*. 2nd Ed. Missouri: Mosby; 2004:49-55.
11. Smith G. Two dentigerous cysts in the mandible of one patient. Case report. *Australian Dent J* 1996;41(5):291-3.
12. Gonzalez S, Spalding P, Payne J, Giannini P. A dentigerous cyst associated with bilaterally impacted mandibular canines in a girl: a case report. *J Med Case Reports* 2011;5:230.
13. Kanth S, Koneru M. Bilateral dentigerous cyst. *Guident* 2011;4(8):41.
14. Boyczuck M, Berger J. Identifying a deciduous dentigerous cyst. *J Amer Dent Assoc* 1995;126(5):643.
15. Behbehani EM, Al-Ramzi AH, Mohamed E A. Oral manifestations of neurofibromatosis: case report. *Dental News* 1997;IV(3):17-21.
16. Ozan B, Muglali M, Celenk P, Gunham O. Postpubertal nonfamilial cherubism and teeth transposition. *J Craniofac Surg* 2010;Sept 21(5):1575-1577.



Dr. Hansford



Dr. Kelsch



Dr. Wiltz

**John T. Hansford, D.M.D.**, is an associate in Pediatric Dentistry of Suffolk County, dental anesthesiology resident, Wyckoff Heights Medical Center, Brooklyn, NY, and former pediatric dentistry resident, Montefiore Medical Center, Bronx, NY.

**Robert D. Kelsch, D.M.D.**, is attending, Department of Dentistry, Oral Pathology at Montefiore Medical Center, Bronx, NY, and assistant professor, Department of Dental Medicine, Division of Oral Pathology, North Shore Long Island Jewish Health System, New Hyde Park, NY.

**Mauricio Wiltz, D.D.S.**, is assistant professor, Department of Dentistry, Division, Oral and Maxillofacial Surgery, Montefiore Medical Center, Bronx, NY.



# The Evolution and Fabrication of Implant-supported Full-arch Hybrid Prostheses

## From Conventional Casted Metal to an All-Ceramic Zirconia

Amanda Ouzer, D.M.D.

---

### ABSTRACT

**Implant-supported, full-arch hybrid prostheses have developed from cast-metal frameworks with acrylic or porcelain to all-ceramic zirconia frameworks. CAD/CAM manufacturing removed the inaccuracies seen with casting and made use of zirconia possible. The materials and processes for prosthodontic fabrication are explained. Zirconia is highly opaque and versatile. However, porcelain-veneered zirconia frameworks have shown higher enamel wear, among other problems. Lithium disilicate has been shown to be more translucent than zirconia. Improved stained and more translucent zirconia frameworks have been produced as well. These promising new methods have gained popularity, but long-term studies are scarce and, thus, more research is required.**

Treatment of edentulous arches has evolved in dentistry from complete dentures and implant over-dentures, to implant-supported, fixed, full-arch bridges and, finally, to the implant-supported hybrid prosthesis. A hybrid prosthesis encompasses a full arch of prosthetic teeth and gingival tissue, completely supported

by implants. It does not cover the palate or other conventional denture landmarks. It offers patients the advantage of a fixed restoration, but it can be removed by the clinician.

Maxillary arch hybrid prostheses face higher demand for function, phonetics and esthetics compared to mandibular arch prostheses. Hybrid prostheses were developed from conventional casted metal frameworks to all-ceramic CAD/CAM-milled zirconia frameworks. This article discusses the history of the hybrid framework, including its materials, design and fabrication, with a focus on the advances of CAD/CAM manufacturing and the zirconia hybrid framework.<sup>1</sup>

### **History and Evolution of Implant-Supported, Full-Arch Hybrid Dentures**

Over the years, multiple methods and materials have been used for hybrid framework design and fabrication. Frameworks were fabricated according to criteria, such as bulk for strength, access for hygiene, minimal display of metal on the facial and occlusal surfaces, and prosthetic space for retention of acrylic resin denture teeth and bases. Drago et al. described guidelines for the hybrid prosthesis, pointing out that the “framework must be fabricated from materials and protocols that allow passive and accurate fit between frameworks and implants and/or abutments.” They must also have adequate thickness buccally/lingually and vertically to resist tensile and compressive forces produced in

function. The amount of thickness is based upon the properties of the material used and the fabrication process. Cantilever design focuses upon the type of material used for the framework, as well as the number and location of implants. Frameworks supported by three or fewer implants should have smaller cantilevers than those supported by six or more implants. Implants and their screw access openings should be positioned as palatal as possible for functional and esthetic purposes.<sup>1,2</sup>

Originally, fixed-hybrid prostheses were created using the lost-wax technique and casting metals. Acrylic resin denture teeth and bases would be applied onto the cast-metal framework. Alternatively, porcelain ceramics would be layered and baked onto the cast-metal framework. Rigid frameworks were desired, and noble alloys such as gold, silver and palladium were used. Palladium/silver alloys were the most favored for the elastic modulus. However, palladium/silver alloys tended to form a green color after porcelain was applied.

Base metal alloys containing titanium or nickel were also used, as they possess significant hardness, high-yield strength and high-elastic moduli compared to noble metals. However, allergic reactions to alloys containing nickel have been reported. Titanium alloys possess similar mechanical properties to cast gold

alloys, but are more difficult to cast due to their high melting points, low density and high reactivity with investment particles. More fractures were detected with titanium frameworks than with gold alloys. Incidents of titanium fractures in hybrid prostheses have been reported to be as high as 15.5%.<sup>1,3</sup>

Common complications with metal-acrylic frameworks are wear and fractures of the resin teeth and bases. Associated factors include poor resin bonding and insufficient support from the metal framework.<sup>3</sup> Porcelain-fused-to-metal hybrid prostheses are more cumbersome to repair than their metal-acrylic counterparts. Further, chipping and de-bonding of porcelain is more difficult to repair than their acrylic counterparts and may require dental laboratory intervention.

Porcelain chipping of cast-metal frameworks can be due to internal casting distortions that create stress on the implants, veneer and the prosthesis. With casting, the metal may expand and contract, causing porosity and distortions. The firing of the porcelain to the metal may also distort the framework. Casting distortions reduce accuracy and the fit of the framework to the implants. A passive fit is very difficult to obtain, and casted frameworks had to be sectioned, indexed and soldered or laser-welded to improve adaptation to the implant platforms.<sup>2</sup>

## Improve your online reputation

**NYSDA**  
Endorsed Service

Demandforce helps you build and leverage your most valuable asset, your online reputation. We automatically collect certified reviews for your practice and publish them across the Web, so anyone searching online can find you. You can also post your reviews to your website or Facebook page. We make it that easy.

**Demandforce**

Demandforce integrates with your practice management solution to deliver results and grow your practice. Visit [demandforce.com/industries/dental/](http://demandforce.com/industries/dental/) today or call them at (800) 210-0355 to learn more!

For more information about this and other Endorsed Programs call: 800-255-2100





---

## CAD/CAM

The creation of CAD/CAM milling drove hybrid prostheses to a new level. The process is mechanized, thus reducing human error, and avoids most distortions and inaccuracies seen in casted-metal frameworks. The system also allows the use of other materials which were too difficult to cast, like titanium. Milled titanium frameworks have significantly fewer complications than casted laser-welded ones.<sup>1</sup> Typically, casted frameworks require joints that are either welded, the fusion of two alloys via high temperature, or soldered.

CAD/CAM technology allows frameworks to be milled from solid blanks of materials. Blanks are more homogenous and contain better physical properties than castings. Frameworks can fit more accurately and machining allows for improved design of the hybrid framework. Homogenous structures allow for longer cantilevers and fewer implants to support the prosthesis. Rigid connectors are eliminated, making the solder and welder joints in casted frameworks unnecessary. Furthermore, CAD/CAM systems allow for easier repair and avoid many of the chipping and de-bonding issues seen with porcelain repair. Whereas casting may require re-baking of porcelain, which can add distortions to the framework, computer software can save records and recreate new copies with the exact same characteristics as the original.<sup>2</sup>

CAD/CAM systems made it possible to use zirconia, a ceramic material that cannot be casted. Zirconia, like other all-ceramic implant prostheses, has gained in popularity in dentistry. Zirconia has a unique ability to stop crack propagation, otherwise known as transformation toughening. Its molecular structure grows more crack-resistant as its temperature rises. Pure zirconia undergoes three states. The monoclinic state, the weakest, exists at temperatures below 1170° C. The tetragonal phase exists at temperatures between 1170° and 2370° C. Cubic, the strongest and most desired state, is reached at 2370° C. Metal oxides, like yttria, are added to stabilize zirconia at room temperature and control phase transformations. Zirconia has high biocompatibility, low bacterial adhesion, low susceptibility to stress fatigue and high flexural strength.<sup>1</sup> Advantages with full ceramics like zirconia include excellent esthetics, high fracture resistance, increased longevity, enhanced stain resistance and greater customizability.<sup>2</sup> Zirconia dioxide has earned the nickname “ceramic steel.”<sup>4</sup>

Dental laboratories use various sized blocks of zirconia that are milled into a framework. These blocks are formed by two methods: uniaxial dry pressing and cold isostatic pressing. In the first method, the zirconia powder is confined in a mold with uniaxial pressure applied. Such a block will have varying densities throughout and is usually square or rectangular. The cold isostatic method allows the zirconia powder to be placed in a deformable mold that experiences pressure in all directions. These blocks are uniformly dense and are usually cylindrical. Zirconia blocks are

considered “green” at this point until they undergo sintering.<sup>5</sup> The “green” zirconia blocks have the most porosity, are the least dense and are the fastest to mill. They produce the least amount of wear on the milling machinery.

Ceramic sintering is the process where heat, and sometimes pressure, is applied to ceramic materials, reducing porosity and increasing their density.<sup>5</sup> In the sintering furnace, zirconia blocks are stabilized and densified into a pre-sintered and fully sintered state. Sintering is first done without pressure to form a pre-sintered state known as hot isostatic postcompaction (HIP) or “white” zirconia. Because HIP has virtually no porosity, HIP zirconia blocks allow for milling at a 1:1 ratio. However, since they are the hardest and densest, they are the slowest to mill and inflict the most wear on the machinery.<sup>4</sup>

The blocks are placed into the CAD/CAM milling machine for processing. CAD/CAM systems have three components: scanning, designing and milling. Scanning can be done using various methods, from intraoral scanners, to a scan of the impression, or a scan of the stone master die. Computer-aided software allows the operator to design the prosthesis step by step digitally. The operator may analyze margins and path of insertion, block out undercuts and do other design procedures. The saved data is then sent for on- or offsite milling.<sup>6</sup>

There are two methods of milling zirconia: soft milling and hard milling. Soft milling uses pre-sintered zirconia milled into an enlarged framework and then sintered to its full strength. One should expect shrinkage of approximately 20% to 25% during sintering, thus frameworks are first milled with larger dimensions using soft milling. On the other hand, hard milling involves using densely sintered HIP zirconia. The framework is machined directly to the desired dimension and full strength.<sup>6</sup> Due to the hardness of the HIP zirconia, hard milling requires longer processing time and places heavy demands on the machine cutting instruments. More manufacturers choose the soft-milling process, likely because of its ease and speed. However, more studies and systematic reviews are needed to determine which process is more accurate.<sup>4</sup>

## The Prosthodontics Process

An implant-supported, one-piece, full-arch prosthesis needs to have the proper occlusal requirements: inter-arch space, bone available for implants, phonetics and esthetic needs. These can be analyzed prior to treatment using CBCT (cone beam computed tomography) scans and various treatment planning protocols. These scans produce three-dimensional images of the dentition.<sup>7</sup> Interocclusal prosthetic space for metal-acrylic frameworks requires about 15 mm to 20 mm per arch, while monolithic zirconia frameworks need 12 mm to 15 mm. Bone reduction to create adequate space can be done during the surgical treatment phase.

---

Then implants should be placed with a lingual angulation allowing for access holes to be projected on occlusal and palatal prosthetic surfaces.<sup>8</sup>

Prosthodontics fabrication involves: 1) the formation of an interim prosthesis; 2) an open-tray implant-level final impression; 3) the creation of a verification jig; 4) the formation of an acrylic PMMA (polymethyl methacrylate) provisional, and finally 5) CAD/CAM manufacturing of the final prosthesis.

The prosthodontics process will now be discussed in greater detail. Several authors suggest creating an interim complete denture prior to implant surgery because it can be used in future steps.<sup>3</sup> Implants are then placed. After healing and osseointegration of implants, transfer copings are placed, connected, or matrixed with various materials such as floss and resin, and then an open-tray impression is taken. A verification jig is used to confirm the accuracy of the master model. The vertical dimension, lip support, and phonetics can be analyzed using the interim denture or formation of a wax bite rim. Next, the denture or wax bite rim can be used for laboratory processing of an acrylic, screw-retained provisional. Alternatively, the interim denture can be transformed chairside into the provisional.

Some recommend having the patient wear the provisional for three weeks to test the function, occlusion, phonetics, midline, tooth contours and dimensions. In the meantime, changes to the provisional can be performed. Once all goals are achieved, it can be scanned and saved as a CAD record. Either an impression of the provisional, a master model of the provisional or the provisional itself may be scanned. The CAD file is then sent for milling of the final zirconia implant-supported, full-arch prosthesis. The underside of the final prosthesis should be convexly shaped between interfaces to allow for proper hygiene.<sup>3,8</sup>

All-ceramic frameworks provide a higher standard of esthetics and are less dense and lighter compared to metal-based frameworks.<sup>9</sup> All-ceramics stain less and are easier to destain than acrylic-titanium frameworks.<sup>10</sup> Because of zirconia's natural shade, there is no risk of the gray effects found with metal-based frameworks. However, zirconia is highly opaque. Therefore, a translucent material, such as porcelain, should be veneered to achieve pleasing esthetics.<sup>11</sup>

#### **Disadvantages of Porcelain-veneered Zirconia**

One ought to be aware that chipping and fracture of porcelain veneered to zirconia is the most reported technical complication;

---

one study reports rates of up to 31.25% in a four-year follow-up.<sup>12</sup> Further, porcelain fractures may be intensified with osseointegrated implant prostheses. Due to functional ankylosis of implants, the cushioning mechanism of the periodontal ligament is missing. Mechanoreceptors are also missing, resulting in reduced proprioception and reduced ability to gauge the bite force. Fracture of the veneering porcelain may therefore be unavoidable because the sensation threshold—the necessary level for any sensation to be detected—is up to 8.75-times higher with implant prostheses.<sup>2,13</sup>

Investigations of the bond strength between core substrates and veneered ceramics reveal more reliable adhesion between metal-ceramic than with zirconia-ceramic combinations. The bonding between metal and veneered porcelain ceramic is considered to be formed by van der Waals forces that mechanically interlock the ceramic with the alloy. Chemical bonds also appear between the ceramic and oxide layer, although the bonding mechanism between veneered ceramics to zirconia has yet to be identified. The zirconia-porcelain veneer bond has not reached the level attained with metal-ceramic bonding.<sup>14</sup>

Veneering porcelain fractures within implant-supported zirconia frameworks is the most common technical complication.



Most authors regard differences in the coefficients of thermal expansion of the veneering porcelain and zirconia core as the strongest probable cause.<sup>1,6,15</sup> The veneer processing technique has been researched recently to establish solutions and alternatives. The over-pressing technique was created to overcome some of these issues. Pressing porcelain onto the zirconia framework resulted in improved fracture resistance.<sup>16</sup> While the conventional layering porcelain technique may have some imperfections, such pressing can result in a more homogenous and improved veneer.<sup>6</sup>

Another disadvantage of porcelain is its tendency to wear opposing material and dentition. In vitro studies comparing porcelain, lithium disilicate and zirconia reported that porcelain has the most enamel wear. Less wear is seen with lithium disilicate, but zirconia caused the least wear on opposing teeth.<sup>17,18</sup>

### Future Methods

Improving the hybrid prosthesis means overcoming the aforementioned disadvantages, such as the opacity of zirconia and the high fracture and wear seen with veneered porcelain. Lithium disilicate has been proposed as a solution since it is highly translucent and wears less than porcelain. The mechanical veneer-pressing technique with lithium disilicate has been shown to be more precise and fracture-resistant than the conventional layering veneer technique. CAD/CAM machining and pressing of lithium disilicate are two proposed options, as industrial produced veneers show fewer faults than hand-layering.<sup>6,19</sup> CAD/CAM milling lithium disilicate veneers onto zirconia significantly increases the mechanical strength of the restoration.<sup>6</sup> One in vitro study indicates no significant difference in chipping and flexural resistance between pressed and CAD-manufactured lithium disilicate. Significant fracture resistance with pressed and CAD-manufactured lithium disilicate. Even better, lithium disilicate is more fracture-resistant than porcelain. However, lithium disilicate could not match the fracture resistance of zirconia.<sup>20</sup>

Another proposed solution is to avoid the veneering material layer altogether. Instead, a monolithic, all-zirconia prosthesis can be manufactured. Without a veneer layer, chipping does not occur.<sup>18</sup> However, translucency of zirconia is significantly lower than that of lithium disilicate, which raises esthetic concerns.<sup>21,22</sup>

Fortunately, developments are being made to produce more translucent zirconia. Some researchers propose refining the microstructure or infusing zirconia with glass.<sup>20</sup> Stained all-zirconia frameworks provide improved esthetics and individual customization for fine detail.<sup>18,23</sup>

The laboratory process for stained zirconia frameworks is as follows. Once the acrylic provisional is scanned, the CAD file is made and the milling process begins. The pre-sintered zirconia framework is fabricated 20% larger to counteract expected shrinkage. It is then stained to allow for detailed coloring. The

framework is then sintered for 10 hours in the oven and glazed to produce a superior prosthesis. This method shows promise, though further testing is needed to support its use. Also, further studies are needed to assess any effect the glazing may cause.<sup>23</sup>

## Conclusion

This article presented the evolution of the implant-supported, full-arch hybrid prosthesis, from conventional cast-metal frameworks with acrylic or porcelain, to an all-ceramic zirconia framework. History, materials and design of the hybrid, its limitations, complications and possible future improvements of the prosthesis were discussed. Casted metal frameworks possessed inaccuracies and fit inadequately. CAD/CAM manufacturing created more homogenous and precise frameworks and made use of zirconia possible. Esthetic zirconia hybrid prostheses are now popular but relatively new. More in vivo, long-term, retrospective studies are needed to evaluate its functional longevity and technical complications. However, we do know that the porcelain-zirconia bond has many disadvantages, such as the high opacity of zirconia and the weakness of the bond.

Recent advances, including the manufacturing of lithium disilicate veneers and more translucent-stained zirconia frameworks, may solve the problems, but all require further investigation. There has not been enough time for long-term studies regarding most of these advancements. ✍

*The author gratefully acknowledges the support of Jason Maltz and family. Queries about this article can be sent to Dr. Ouzer at amandaouzer@gmail.com.*

## REFERENCES

1. Drago C, Howell K. Concepts for designing and fabricating metal implant frameworks for hybrid implant prostheses. *J Prosthodontics* 2012;21:413-424.
2. Maló P, Nobre MdA, Borges J, Almeida R. Retrievable metal ceramic implant-supported fixed prostheses with milled titanium frameworks and all-ceramic crowns: retrospective clinical study with up to 10 years of follow-up. *J Prosthodontics* 2012;21:256-264.
3. Rojas-Vizcaya F. Full zirconia fixed detachable implant-retained restorations manufactured from monolithic zirconia: clinical report after two years in service. *J Prosthodontics* 2011;20:570-576.
4. Helvey GA. Zirconia and computer-aided design/computer aided manufacturing (CAD/CAM) dentistry. *Functional Esthetics and Restorative Dentistry* 2007;1(3):28-39.
5. Brown C. Sintering furnaces. *Inside Dental Technology* 2012;3(1). Web.
6. Al-Almeh B, Lyons K, Swain M. Review Article: Clinical trials in zirconia: a systematic review. *J Oral Rehab* 2010;37:641-652.
7. Technical Description of CBCT from University of Manchester. *J Canadian Dent Assoc* 2006;72(1):75-80.
8. Tischler M, Ganz SD, Patch C. An ideal full-arch tooth replacement option: CAD/CAM zirconia screw-retained implant bridge. *Dentistry Today.com* 2013;1:2-7.
9. Hassel AJ, Shahin R, Kreuter A, Rammelsberg P. Rehabilitation of an edentulous mandible with an implant-supported fixed prosthesis using an all-ceramic framework: a case report. *Quintessence International* 2008;39(5):421-426.
10. Chang PP, Henegbarth EA, Lang LL. Maxillary zirconia implant fixed partial dentures opposing an acrylic resin implant fixed complete denture: a two-year clinical report. *J Prosthodontics* 2007;97(6):321-330.
11. Papaspyridakos P, Lal K. Complete arch implant rehabilitation using subtractive rapid prototyping and porcelain fused to zirconia prosthesis: a clinical report. *J Prosthetic Dent* 2008;100(3):165-72.
12. Papaspyridakos P, Chen CJ, Chuang SK, Weber HP, Gallucci GO. A systematic review of biologic and technical complications with fixed implant rehabilitations for edentulous patients. *Int J Oral and Maxillofac Implants* 2012;27:102-110.

13. Takaba M, Tanaka S, Ishiura Y, Baba K. Implant-supported fixed dental prostheses with CAD/CAM-fabricated porcelain crown and zirconia-based framework. *J Prosthodontics* 2013;22:402-407.
14. Aktas G, Sahin E, Vallittu P, Özcan M, Lassila L. Effect of colouring green stage zirconia on the adhesion of veneering ceramics with different thermal expansion coefficients. *Int J Oral Science* 2013;5:236-241.
15. Guess PC, Att W, Strub JR. Zirconia in fixed implant prosthodontics. *Clin Implant Dent and Related Research* 2012;14(5):633-645.
16. Komine F, Blatz MB, Matsumara H. Current status of zirconia-based fixed restorations. *J Oral Science* 2010;52(4):531-539.
17. Kim MJ, Oh SH, Kim JH, Ju SW, Seo DG, Jun SH, Ahn JS, Ryu JJ. Wear evaluation of the human enamel opposing different Y-TZP dental ceramics and other porcelains. *J Dentistry* 2012;40:979-988.
18. Jung YS, Lee JW, Choi YJ, Ahn JS, Shin SW, Huh JB. A study on the in-vitro wear of the natural tooth structure by opposing zirconia or dental porcelain. *J Advanced Prosthodontics* 2010;2:111-115.
19. Schmitter M, Mueller D, Rues S. Chipping behavior of all-ceramic crowns with zirconia framework and CAD/CAM manufactured veneer. *J Dent* 2012;40:154-162.
20. Zhang Y, Lee JJW, Srikanth R, Lawn BR. Edge chipping and flexural resistance of monolithic ceramics. *Dental Materials* 2013;29:1201-1208.
21. Baldissara P, Llukacej A, Ciocca L, Valandro FL, Scotti R. Translucency of zirconia copings made with different CAD/CAM system. *J Prosthetic Dent* 2010;104(1):6-12.
22. Cheng CW, Chien CH, Chen CJ, Papaspyridakos P. Complete-mouth implant rehabilitation with modified monolithic zirconia implant-supported fixed dental prostheses and an immediate-loading protocol: a clinical report. *J Prosthet Dent* 2013;109:347-352.
23. Tischler M. Prettau Bridge. [www.tischlerdentallab.com](http://www.tischlerdentallab.com) Accessed 12/23/2013.



**Amanda Ouzer, D.M.D.**, is employed full time at Boriken Health Center in East Harlem, NY. She was a PGY-1 resident at Interfaith Medical Center, Brooklyn, NY, graduating in 2014.